

# A Rare Case of Bladder Endometriosis Mimicking a Bladder Tumor

© Mehmet Erhan Aydın<sup>1</sup>, © Aykut Aykaç<sup>2</sup>, © Coşkun Kaya<sup>2</sup>, © Mustafa Sungur<sup>2</sup>, © Zeliha Burcu Sarı<sup>3</sup>

<sup>1</sup>Eskişehir City Hospital, Clinic of Urology, Eskişehir, Türkiye

<sup>2</sup>Health Sciences University, Eskişehir City Health Applications Research Center, Eskişehir, Türkiye

<sup>3</sup>Eskişehir City Hospital, Clinic of Pathology, Eskişehir, Türkiye

## Abstract

The presence of endometrial stroma and/or glandular epithelium in organs other than the uterus is called endometriosis. Urinary system endometriosis is observed in approximately 1% of women with endometriosis and is most commonly seen in the bladder. A 27-year-old female patient was admitted to the urology clinic with cyclic complaints of painful and frequent urination. Ultrasonography revealed a lesion extending to the lumen of approximately 15x10 mm in the left side wall of the bladder. On cystoscopy, a suspicious area with irregular borders was observed, approximately 15 mm, at the left-posterior lateral wall of the bladder, and transurethral resection was performed. The pathological result of the patient was reported as bladder endometriosis. Although rare, bladder endometriosis should be considered in the differential diagnosis, especially in women of reproductive age with cyclic urological complaints.

**Keywords:** Bladder, endometriosis, tumor

## Introduction

The presence of endometrial stroma and/or glandular epithelium in organs other than the uterus is called endometriosis. Endometriosis rarely occurs in extragonadal organs, such as the bladder and intestinal tract, causing organ-specific symptoms (1).

From studies conducted in Europe, urinary system endometriosis was observed in 0.3-12% of women with endometriosis (2,3). The incidence of urinary system endometriosis is as follows: 85% bladder, 9% ureter, 4% kidney, 2% urethra (4).

Bladder endometriosis (BE) is defined by the presence of endometriotic tissue in the detrusor muscle of the bladder (5) and is most commonly seen in the bladder base and bladder dome (6). Typically, women with BE present with dysuria, frequency, hematuria, and urinary incontinence (7,8). Anamnesis and imaging methods are important in the diagnosis of BE. The differential diagnosis includes intraluminal bladder lesions, urinary tract infection, urinary tract stone, and interstitial cystitis (9).

The aim of BE treatment is to relieve symptoms and prevent possible kidney damage. Treatment can be conservative, medical, or surgical by evaluating the patient and the extent of endometriosis.

## Case Presentation

A 27-year-old female patient was admitted to the urology clinic with complaints of painful urination and frequent urination, which started every month with her menstrual period for approximately 1 year. There was no disease or operation history in the medical history. In terms of gynecological history, she had 3 pregnancies, 2 deliveries, and 1 abortion. No erythrocyturia or leukocyturia was observed during complete urinalysis. Ultrasonography revealed a lesion extending to the lumen of approximately 15x10 mm in the left side wall of the bladder. On cystoscopy, a suspicious area with irregular borders was observed, approximately 15 mm, at the left-posterior lateral wall of the bladder, and transurethral resection (TUR) was performed (Video 1). During the resection, brown gelatinous material was observed (Figure 1). The pathology result of the patient was reported as BE (Figure 2-4). No pathology was found in the gynecological

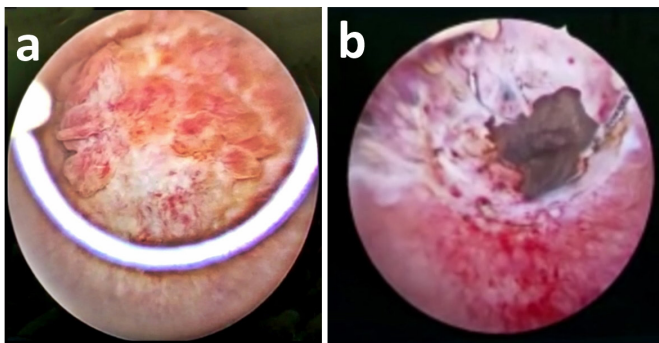
**Correspondence:** Mehmet Erhan Aydın MD, Eskişehir City Hospital, Department of Urology, Eskişehir, Türkiye

**Phone:** +90 222 611 40 00 **E-mail:** merhanaydin@gmail.com **ORCID-ID:** orcid.org/0000-0002-3567-9987

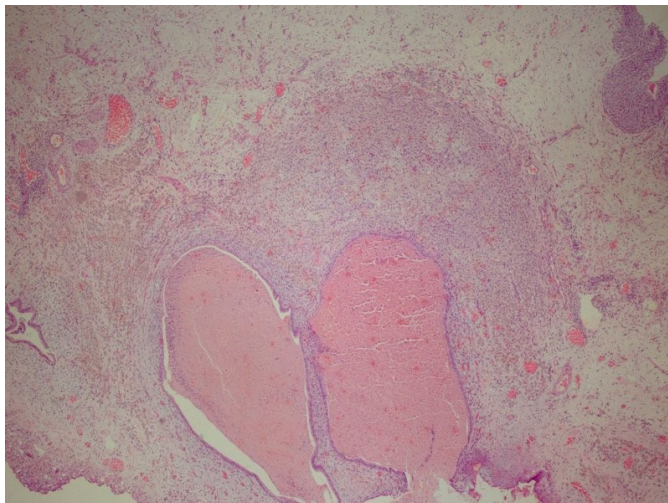
**Received:** 26.04.2023 **Accepted:** 11.09.2023

**Cite this article as:** Aydın ME, Aykaç A, Kaya C, Sungur M, Sarı ZB. A Rare Case of Bladder Endometriosis Mimicking Bladder Tumor. J Urol Surg 2023;10(4):349-351.

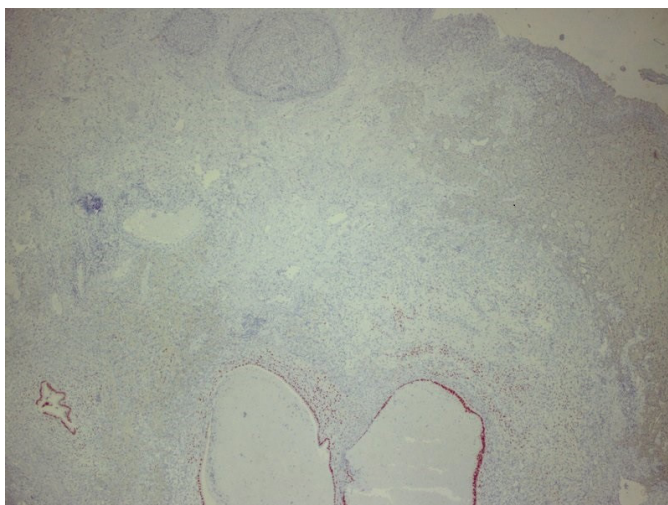




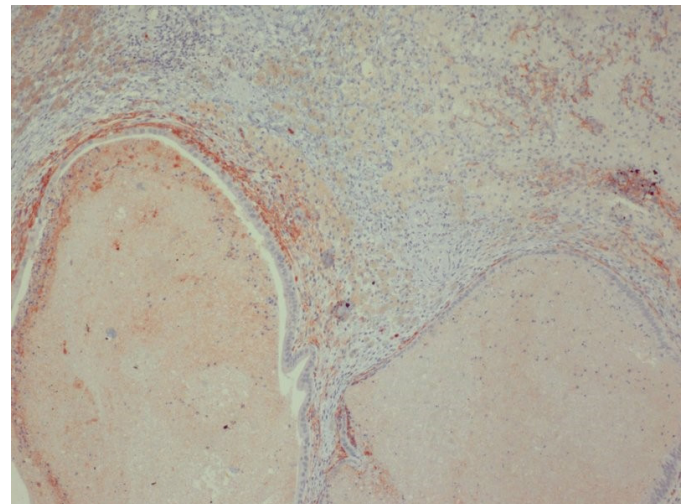
**Figure 1.** a. On cystoscopy, a suspicious area with irregular borders was seen, approximately 15 mm, at the left- posterior lateral wall of the bladder; b. During the resection procedure, brown gelatinous material which is typical endometriosis appearance was seen



**Figure 2.** In the upper right corner, cystic dilated gland structures lined with bladder urothelial epithelium and endometrial epithelium in the lamina propria (x40)



**Figure 3.** Immunohistochemical positivity of estrogen hormone receptor (Clone SP5) in the endometrial epithelium lining the cystic gland structures in the lamina propria (x40)



**Figure 4.** CD10 immunohistochemical positivity in the endometrial stroma surrounding gland structures (x100)

evaluation of the patient. The case was evaluated as primary BE. A gonadotropin-releasing hormone (GnRH) analog was started as additional treatment. The patient did not have any symptoms during the 3-month follow-up after surgery. The follow-up of the patient continues.

## Discussion

BE is observed in women of reproductive age and usually around 35 years of age. While the cases that are accepted as primary are found at a rate of 11%, secondary cases are mostly detected because of a reason such as cesarean section or previous pelvic surgery. The frequency of involvement of endometriosis in the urinary system is 85% in the bladder, 9% in the ureter, 4% in the kidney, and 2% in the urethra (4).

Patients with BE present to the clinic with dysuria, frequent urination, bladder pain, and less frequent hematuria, urgency, and urinary incontinence (7,8). Dysuria has been reported in 21-69% of patients. Hematuria is a less frequent symptom reported in 0-35% of cases and occurs when the bladder lesion infiltrates the mucosa. Although ultrasonography is the first choice at diagnosis, magnetic resonance imaging may be helpful, especially in cases with suspected ureteral involvement (1). In patients who are scheduled for cystoscopy, it would be more appropriate to evaluate the lesions by considering the menstrual cycle (10).

Treatment should be planned by considering the patient's age, pregnancy desire, and the spread of the disease. Medical treatment of BE reduces symptoms and is used palliatively. Postmenopausal women with a single bladder lesion 5 mm are ideal candidates for medical treatment. The most commonly

used drugs are GnRH agonists and antagonists, progestins, and combined oral contraceptives (10).

The aim of surgical treatment is the complete removal of the endometrial tissue, and it is the only cure method for BE (10). Surgical treatment options include TUR of the bladder, partial cystectomy, and total cystectomy. If possible, the recommended treatment is complete resection with transurethral surgery (11). A combination of TUR-M and hormone therapy may be preferred in young patients who want to preserve fertility (10). In cases where endometriosis invades the urothelial mucosa from the outside of the bladder, TUR-M treatment is not sufficient and partial cystectomy should be considered (12).

Follow-up is recommended for women with deep (e.g. bladder) and ovarian endometriosis, but there is no set follow-up program in the guidelines. The frequency and type of follow-up should be evaluated according to the severity of the disease and symptoms (13).

## Conclusion

Although rare, BE should be considered in the differential diagnosis, especially in women of reproductive age who have pelvic pain in the cyclical cycle and a mass in the bladder.



Video 1. <https://youtu.be/ih1oBnoksvQ>

## Ethics

**Informed Consent:** Informed consent was obtained from the patient.

**Peer-review:** Externally and internally peer-reviewed.

## Authorship Contributions

Surgical and Medical Practices: M.E.A., M.S., Z.B.S., Concept: M.E.A., A.A., Design: A.A., M.S., Z.B.S., Data Collection or Processing: A.A., Z.B.S., Analysis or Interpretation: C.K., M.S., Literature Search: C.K., M.S., Writing: M.E.A., C.K.

**Conflict of Interest:** No conflict of interest was declared by the authors.

**Financial Disclosure:** The authors declared that this study received no financial support.

## References

1. Leone Roberti Maggiore U, Ferrero S, Candiani M, Somigliana E, Viganò P, Vercellini P. Bladder Endometriosis: A Systematic Review of Pathogenesis, Diagnosis, Treatment, Impact on Fertility, and Risk of Malignant Transformation. *Eur Urol* 2017;71:790-807.
2. Knabben L, Imboden S, Fellmann B, Nirgianakis K, Kuhn A, Mueller MD. Urinary tract endometriosis in patients with deep infiltrating endometriosis: prevalence, symptoms, management, and proposal for a new clinical classification. *Fertil Steril* 2015;103:147-152.
3. Gabriel B, Nassif J, Trompoukis P, Barata S, Wattiez A. Prevalence and management of urinary tract endometriosis: a clinical case series. *Urology* 2011;78:1269-1274.
4. Maccagnano C, Pellucchi F, Rocchini L, Ghezzi M, Scattoni V, Montorsi F, Rigatti P, Colombo R. Diagnosis and treatment of bladder endometriosis: state of the art. *Urol Int* 2012;89:249-258.
5. Fedele L, Piazzola E, Raffaelli R, Bianchi S. Bladder endometriosis: deep infiltrating endometriosis or adenomyosis? *Fertil Steril* 1998;69:972-975.
6. Guerriero S, Condous G, van den Bosch T, Valentin L, Leone FP, Van Schoubroeck D, Exacoustos C, Installé AJ, Martins WP, Abrao MS, Hudelist G, Bazot M, Alcazar JL, Gonçalves MO, Pascual MA, Ajossa S, Savelli L, Dunham R, Reid S, Menakaya U, Bourne T, Ferrero S, Leon M, Bignardi T, Holland T, Jurkovic D, Benacerraf B, Osuga Y, Somigliana E, Timmerman D. Systematic approach to sonographic evaluation of the pelvis in women with suspected endometriosis, including terms, definitions and measurements: a consensus opinion from the International Deep Endometriosis Analysis (IDEA) group. *Ultrasound Obstet Gynecol* 2016;48:318-332.
7. Maccagnano C, Pellucchi F, Rocchini L, Ghezzi M, Scattoni V, Montorsi F, Rigatti P, Colombo R. Ureteral endometriosis: proposal for a diagnostic and therapeutic algorithm with a review of the literature. *Urol Int* 2013;91:1-9.
8. Leone Roberti Maggiore U, Ferrero S, Salvatore S. Urinary incontinence and bladder endometriosis: conservative management. *Int Urogynecol J* 2015;26:159-162.
9. Leonardi M, Espada M, Kho RM, Magrina JF, Millischer AE, Savelli L, Condous G. Endometriosis and the Urinary Tract: From Diagnosis to Surgical Treatment. *Diagnostics (Basel)* 2020;10:771.
10. Deger M, Ok F, Izol V. Üriner Sistem Endometriozisi. In: Anılır E, editor. *Endometriozis Tedavisinde Güncel Yaklaşımlar*. Ankara, Turkey: Akademisyen Kitabevi; 2019. p. 107-17.
11. Pérez-Utrilla Pérez M, Aguilera Bazán A, Alonso Dorrego JM, Hernández A, de Francisco MG, Martín Hernández M, de la Peña Barthel J. Urinary tract endometriosis: clinical, diagnostic, and therapeutic aspects. *Urology* 2009;73:47-51.
12. Endo Y, Akatsuka J, Obayashi K, Takeda H, Hayashi T, Nakayama S, Suzuki Y, Hamasaki T, Kondo Y. Efficacy of Laparoscopic Partial Cystectomy with a Transurethral Resectoscope in Patients with Bladder Endometriosis: See-Through Technique. *Urol Int* 2020;104:546-550.
13. Becker CM, Bokor A, Heikinheimo O, Horne A, Jansen F, Kiesel L, King K, Kvaskoff M, Nap A, Petersen K, Saridogan E, Tomassetti C, van Hanegem N, Vulliamoz N, Vermeulen N; ESHRE Endometriosis Guideline Group. ESHRE guideline: endometriosis. *Hum Reprod Open* 2022;2022:hoac009.