

# Ureterocele in Adults: A Case Study and Review of Clinical Presentations and Management Options

© Antonius Galih Pranesdha Putra, © Edwin Ongkorahardjo, © Anastasia Pearl Angeli

Adi Husada Undaan Wetan, Department of Urology, East Java, Indonesia

## Abstract

Ureterocele is a cystic dilatation of the distal ureter and is a rare cause of urinary tract obstruction. It is commonly found in infants and young children and is more prevalent in females than in males. This report presents the case of a 59-year-old woman who suffered right flank pain and was diagnosed with ureterocele. The patient was treated with endoscopic surgery and unroofing of the ureterocele.

**Keywords:** Ureterocele, flank pain, unroofing ureterocele

## Introduction

Ureterocele is a cystic dilatation of the submucosal distal ureter and is an uncommon cause of urinary tract obstruction. Ureterocele occurs more frequently in infants and early children than in adults and teenagers, and it affects females more frequently than males (1,2). The prevalence rate of ureterocele is 1 per 4000 children, with the prevalence being 4 times higher in females where the left side is slightly dominant and 10% of the cases are bilateral (3,4).

The common symptoms of ureterocele range from incontinence, recurrent urinary tract infections (UTIs), failure to thrive, urinary tract calculus, and irregular flank pain. Without proper early diagnosis and treatment during childhood, ureterocele could present along with secondary complications such as pyonephrosis, urosepsis, stones, urinary retention, or chronic renal failure. Hence, an individualized treatment is needed for ureterocele patients (5). Ureterocele incisions, open technique, endoscopic therapy, and transurethral diathermy incision are among the available therapeutic methods that have produced positive results (6). Endoscopic surgery and unroofing can be performed to relieve obstruction and prevent complications such as UTIs and renal damage (7,8).

Ureteroceles are classified on the basis of their location and association with other anatomical abnormalities.

The classification system of the American Academy of Pediatrics is commonly used, where the ureteroceles are classified into intravesical ureteroceles (occur at the normal vesicoureteric junction position, bilateral and occur mostly in adults) and extravesical ureteroceles (occur abnormally low and medial, close to the bladder neck or urethra, predominantly associated with a duplex kidney) (9). The latter type might result in blockage of the entire renal tract due to prolapse into the bladder (10-12). In 1954, Ericsson classified ureterocele as (1) simple ureterocele, in which the orifice is located on the trigone, and (2) ectopic ureterocele, in which the orifice is located at the bladder neck or posterior urethra (13,14). Furthermore, Bruézière classified ureterocele into the following: 1) type A, intravesical ureterocele on a single ureter; 2) type B, ectopic ureterocele on a single ureter; 3) type C, intravesical ureterocele on pyeloureteral duplication; and 4) type D, ectopic ureterocele on pyeloureteral duplication (15).

Understanding the different types and classifications of ureteroceles is important for accurate diagnosis and appropriate management. This case report highlights the uncommon occurrence of ureterocele in adults. Despite the absence of urinary issues, the study underscores the significance of considering ureterocele as a potential urinary tract blockage in adult patients presenting with flank pain. In addition, with various symptoms and presentations of ureterocele, this case

**Correspondence:** Antonius Galih Pranesdha Putra MD, Adi Husada Undaan Wetan, Department of Urology, East Java, Indonesia

**E-mail:** galihpranesdha@gmail.com **ORCID-ID:** orcid.org/0009-0006-1829-5013

**Received:** 19.02.2024 **Accepted:** 23.10.2023

**Cite this article as:** Putra AGP, Ongkorahardjo E, Angeli AP. Ureterocele in Adults: A Case Study and Review of Clinical Presentations and Management Options.

could be used as a perspective of a case with a single symptom of right flank pain in adults.

### Case Presentation

We present the case of a 59-year-old woman who presented with right flank pain and was diagnosed with ureterocele. Laboratory investigation showed normal results. To test the condition of this woman, computed tomography (CT) intravenous pyelogram (CT IVP) was performed and showed dilatation of the right distal ureter or ureterovesical junction suggestively as ureterocele, as shown in Figure 1 and Figure 2. After diagnosis, the patient underwent endoscopic surgery and unroofing of the ureterocele. The patient had no complaints during the postoperative control session.

Treatment options for ureterocele include upper pole partial nephrectomy, endoscopic incision, complete bladder reconstruction, and non-operative (conservative) treatment (16). The choice of treatment should be individualized for each case.

### Discussion

Ureteroceles depicts a particular clinical challenge in terms of diagnosis and management because of the various types and presentations; hence, the treatment has to be customized based on the individual needs of each case. With various types and presentations, the cause of ureterocele remains controversial. There are two arguments regarding the etiology of ureterocele: one is congenital and the other is an acquired lesion. The congenital argument is supported by more evidence than the acquired argument (17).

One of the widely accepted theories regarding the pathogenesis of ureterocele is the regression failure of the Chwalla membrane, a membrane between the urogenital sinus and the developing ureteral bud. Chwalla proposed the etiology of ureterocele, where the development of ureterocele is caused by the obstruction of a membrane closing the mouth of the ureter in the embryo. However, this does not justify the stenotic case of ureterocele because it does not clarify the presence of a patulous ureteric orifice in the urethra (13). Considering that

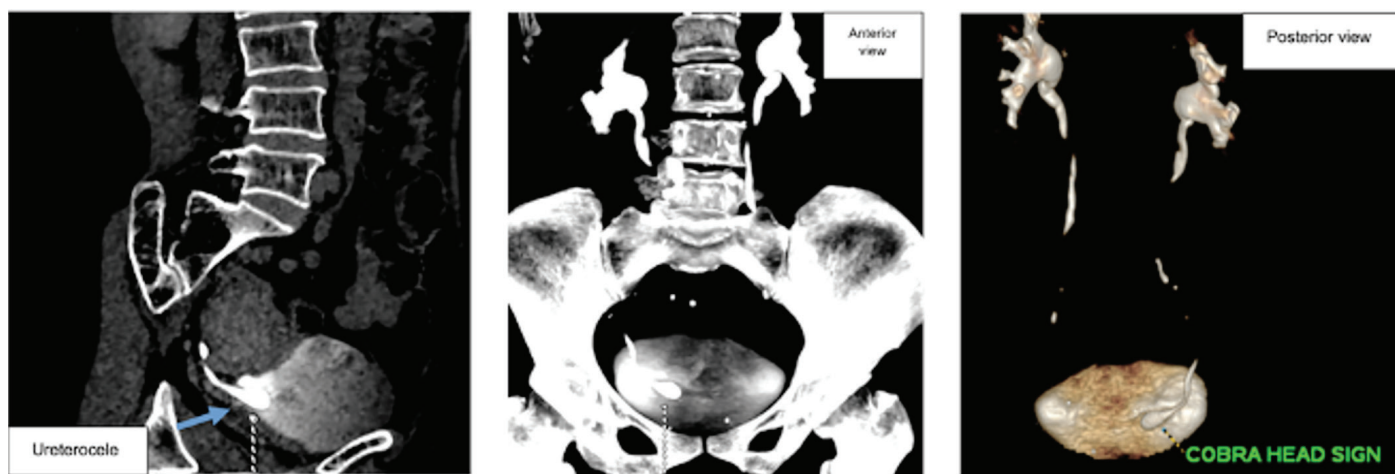


Figure 1. CT IVP imaging

CT IVP: Computed tomography intravenous pyelogram

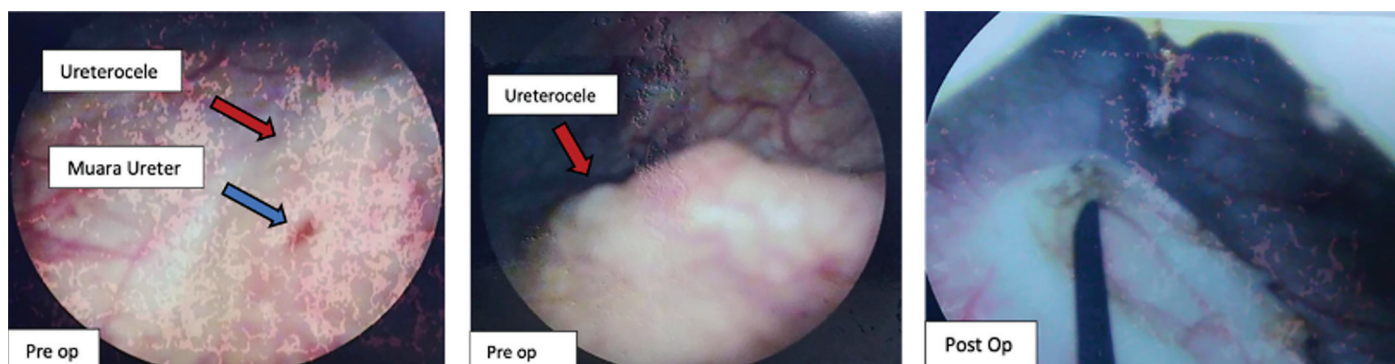


Figure 2. Endoscopic imaging showed an ureterocele on the right UVJ

UVJ: Ureterovesical junction

ureteroceles in duplex systems only affect the upper bud and not the lower bud, the etiology foundation of ureteroceles is correlated to their location on the mesonephric duct (Wolffian duct) (18). A previous study stated that ureterocele is caused by malformation of the ureteral and urogenital sinus (19). On the other hand, acquired ureterocele is hypothesized by an increase in intramural pressure and mucosal herniation of the ureter, which is caused by a sequel of distal obstruction such as calculus (20).

The diagnosis of ureterocele in pediatric patients can be made through imaging studies such as ultrasound, voiding cystourethrography, or IVP. Treatment options for ureterocele in pediatric patients depend on the severity of symptoms and the presence of complications. Conservative management may be considered for asymptomatic cases, whereas surgical intervention, such as endoscopic incision or complete reconstruction at the bladder level, may be necessary for symptomatic cases or those with complications.

The management of ureterocele is varied. The management option is based on the patient's presentation, age, ureterocele type, presence of contagion or infection, stones, and duplex kidney (5). Operative treatment options for ureteroceles include incision, multiple punctures, unroofing, and resection (21). Endoscopic procedure as a minimally invasive approach provides early decompression for ureterocele patients (22). A previous study stated that minimally invasive procedures have been proven to be safe, effective, and successfully managed in ureteroceles patients (5,21-27).

While previous studies found that minimally invasive surgery is considered successful without recurrent symptoms, other studies found that some cases of ureteroceles need secondary surgery after minimally invasive procedures (24,27,28). Minimally invasive procedures, such as endoscopic incision, are not considered a definitive management for ectopic ureterocele patients with duplex systems and preoperative reflux (26). Nevertheless, experts agree that the management of ureteroceles aims to prevent UTIs, relieve the blockage of renal parenchyma, prevent and treat VUR, and minimize surgical procedures and morbidity (13).

In this case, the patient underwent endoscopic surgery and unroofing of the ureterocele. Endoscopic incision is a minimally invasive surgery that requires making a minor surgical cut in the ureterocele to relieve the obstruction and improve urine drainage. After endoscopic incision of the ureterocele, the patient may experience relief of symptoms and improvement in urinary flow. The procedure resulted in no postoperative complaints from the patient.

The clinical presentation of ureterocele in adults is usually incidental, but it can sometimes present with intermittent flank

pain, recurrent UTI, or calculus. The patient only complained about flank pain, and CT IVP showed dilatation of the right distal ureter and an indication of cobra head abnormality. This case could be a reference to diagnose patients with flank pain complaint properly, so further symptoms of ureteroceles could be avoided.

### Study Limitations

The limitation of this research is that it is based on a single case study, which may limit the generalizability of the findings. Case studies provide valuable insights into individual cases but may not represent the broader population. Therefore, the conclusions drawn from this research should be interpreted with caution and further studies are needed to validate the findings and establish more robust conclusions. Further research is needed to enhance our understanding of ureterocele and optimize its management strategies.

### Conclusion

The case reported a 59-year-old woman who presented with right flank pain and was diagnosed with ureterocele. After endoscopic incision and unroofing of the ureterocele to relieve the symptoms, the patient is declared asymptomatic. It is important to note that ureterocele in adults is a rare condition, and its diagnosis and management can be challenging because of its variable presentations. Follow-up is necessary to monitor for recurrence of symptoms or complications. Overall, the diagnosis and management of ureterocele require a comprehensive approach, considering the patient's age, symptoms, and individual characteristics.

### Ethics

**Informed Consent:** Informed consent was obtained from the patient.

### Authorship Contributions

Surgical and Medical Practices: A.G.P.P., E.O., A.P.A., Concept: A.G.P.P., E.O., A.P.A., Design: A.G.P.P., E.O., A.P.A., Analysis or Interpretation: A.G.P.P., E.O., A.P.A., Literature Search: A.G.P.P., Writing: A.G.P.P.

**Conflict of Interest:** No conflict of interest was declared by the authors.

**Financial Disclosure:** The author declared that this study received no financial support.

### References

1. Belhassen S, Elezzi A, Hidouri S, Laamiri R, Mosbahi S, Ksaa A, Sahnoun L, Mekki M, Belguith M, Nouri A. Urétérocele sur uretère simplex chez l'enfant: aspects cliniques et thérapeutiques [Ureterocele associated with

- simplex ureter in children: clinical and therapeutic features]. *Pan Afr Med J* 2021;38:345.
2. Wang J, Zhao Y, Chen Z, Geng H, Fang X. Ureterocele with duplex collecting systems and febrile urinary tract infection risk. *Pediatr Surg Int* 2023;39:200.
  3. Misseri R, Rink RC. Chapter 58. Complications of Ureteral Reimplantation, Antireflux Surgery, and Megaureter Repair. In: *Complications of Urologic Surgery (Fourth Edition)* [Internet]. 2010. p. 685-695. Available from: <https://www.sciencedirect.com/science/article/abs/pii/B9781416045724000583>
  4. Schultz K, Toda LY. Genetic Basis of Ureterocele. *Curr Genomics* 2016;17:62-69.
  5. Chowdhary SK, Kandpal DK, Sibal A, Srivastava RN. Management of complicated ureteroceles: Different modalities of treatment and long-term outcome. *J Indian Assoc Pediatr Surg* 2014;19:156-161.
  6. Abrahamsson LO, Rosenkilde Olsen P, Mathiesen FR. Ureterocele in adults. A follow-up study of 28 adult patients treated with transurethral diathermy incision. *Scand J Urol Nephrol* 1981;15:239-242.
  7. Cooper CS. *Ureterocele Treatment & Management*. Medscape, 2020.
  8. Nast KJ, Marietti-Shepherd S, Kaplan G. Scissor Ureterocele Unroofing Endoscopic Technique: A Novel Technique for Minimally Invasive Ureterocele Treatment. *Videourology* 2017;31:vid.2017.0007.
  9. Society for Maternal-Fetal Medicine; Ghaffari N. Ectopic ureterocele. *Am J Obstet Gynecol* 2021;225:B14-B15.
  10. Xie D. Ureterocele: Review of Presentations, Types and Coexisting Diseases. *Int Arch Urol Complicat* 2017;3.
  11. Niknejad M, Gaillard F. Ureterocele. In: *Radiopaedia.org*. Radiopaedia.org; 2008.
  12. Timberlake MD, Corbett ST. Minimally invasive techniques for management of the ureterocele and ectopic ureter: upper tract versus lower tract approach. *Urol Clin North Am* 2015;42:61-76.
  13. Shokeir AA, Nijman RJ. Ureterocele: an ongoing challenge in infancy and childhood. *BJU Int* 2002;90:777-783.
  14. Ali SI, Iqbal N, Kala MS, Dobs MIL, Raffay EA, Khan M, Ali T, Iftikhar MJ, Sethuraman P, Akhter S. Management of Ureteroceles: Review Article. *J Biol Today's World* [Internet] 2020;9:1-4. Available from: <https://www.iomcworld.org/articles/management-of-ureteroceles-review-article.pdf>
  15. Oueslati A, Saadi A, Chakroun M, Zaghbib S, Bouzouita A, Derouiche A, Slama MRB, Ayed H, Chebil M. Endoscopic meatotomy in the treatment of ureterocele: results in adult patients. *Pan Afr Med J* 2020;36:243.
  16. Hariwibowo R, Rahardjo HE. Endoscopic incision of protruding right ureterocele in a single collecting system: a case report. *Med J Indones* 2017;25:240-244.
  17. Wershub LP, Kirwin TJ. Ureterocele, its etiology, pathogenesis and diagnosis. *Am J Surg* 1954;88:317-327.
  18. Tanagho EA. Embryologic basis for lower ureteral anomalies: a hypothesis. *Urology* 1976;7:451-464.
  19. Jain S, Chen F. Developmental pathology of congenital kidney and urinary tract anomalies. *Clin Kidney J* 2018;12:382-399.
  20. Chauhan G, Levy I, Samuel SW. Ureterocele as a cause of chronic intractable abdominal pain. *BMJ Case Rep* 2021;14:e245262.
  21. Subihardi LME, Rahman IA, Yogiswara N, Rizaldi F, Tarmono. Prolapsed ureterocele mimicking a vulval mass in young female with complete duplex system and ureteral stone: A case report. *Int J Surg Case Rep* 2023;106:108087.
  22. Caione P, Gerocarni Nappo S, Collura G, Matarazzo E, Bada M, Del Prete L, Innocenzi M, Mele E, Capozza N. Minimally Invasive Laser Treatment of Ureterocele. *Front Pediatr* 2019;7:106.
  23. Quitral VM, Mena DJA, Manriquez CL, Mela SMJ, Ammann RR, Navarrete ML, Montedónico RS. Minimally invasive treatment of pediatric obstructive ureterocele: A 20-year experience. *J Pediatr Surg Open* 2023;4.
  24. Yuri P, Utama ETP. A complete duplicated collecting system with giant ureterocele in adult: Case report. *Int J Surg Case Rep* 2021;79:49-52.
  25. Katwal S, Ghimire A, Shrestha K, Kansakar R, Amatya S. Unraveling recurrent urinary tract infection in adulthood: a rare case report of unilateral partial duplex collecting system with ureterocele. *Ann Med Surg (Lond)* 2023;85:5214-5218.
  26. Byun E, Merguerian PA. A meta-analysis of surgical practice patterns in the endoscopic management of ureteroceles. *J Urol* 2006;176:1871-7; discussion 1877.
  27. Aikins K, Taghavi K, Grinlinton M, Reed P, Price N, Upadhyay V. Cystoscopic transurethral incision in simplex and duplex ureteroceles-is it the definitive procedure? *J Pediatr Urol* 2019;15:560.e1-560.e6.
  28. Coplen DE, Barthold JS. Controversies in the management of ectopic ureteroceles. *Urology* 2000;56:665-668.