

Robot Assisted Bladder Diverticulectomy Seven Year After Radical Prostatectomy

© Asher Mandel¹, © Kaushik Prabhav Kolanukuduru¹, © Manish Kumar Choudhary¹, © Swati Bhardwaj², © Vinayak Wagaskar¹, © Avinash Reddy¹, © Ash Tewari¹

¹The Milton and Carroll Petrie Department of Urology at the Icahn School of Medicine at Mount Sinai, New York, USA

²Icahn School of Medicine at Mount Sinai, Department of Pathology, New York, USA

Abstract

The impact of radical prostatectomy on the natural history of the neurogenic bladder is not well understood. Neurogenic bladder can manifest as detrusor sphincter dyssynergia. When left untreated, neurogenic bladder can cause bladder hypotonia. Chronically high volumes and pressures can result in the formation of bladder diverticula. Diverticula, if present, are usually located at the lateral walls of the bladder. In this case, a 77-year-old man with a neurogenic bladder presented with a symptomatic bladder diverticulum at the dome, which developed years after radical prostatectomy. A complex history made him a candidate for definitive treatment; thus, a diverticulectomy was performed. The history and operative and pathological findings are discussed.

Keywords: Neurogenic bladder, robotic diverticulectomy, radical prostatectomy, clean intermittent catheterization, cystogram

Introduction

Bladder diverticula are out-pouches of the bladder mucosa that occur through defects in the detrusor muscle fibers (1). This mucosal herniation can occur because of congenital or acquired factors. In the congenital variant, they are often located superolateral to the ureteral orifice and are associated with vesicoureteral reflux. In adults, bladder diverticula are associated with increased pressure in the bladder, either due to obstruction or detrusor sphincter dyssynergia (DSD). They are usually asymptomatic at initial presentation but can cause urinary tract infections (UTIs) or stone disease over time (1). Approximately 1% of urothelial carcinomas are found within bladder diverticula, and such cases have a poorer prognosis (2). 90% of all cases of bladder diverticula occur in adults, with men being disproportionately affected with a 9:1 ratio (1).

Spinal cord injury causes neurogenic bladder and DSD (3). Dyssynergia results from the loss of coordination between detrusor contraction and urinary sphincter relaxation (4). This can cause ineffective bladder emptying, leading to increased bladder volumes and pressures. Over time, the detrusor can stretch and become hypocontractile (5). Bladder diverticula can

also occur because of an untreated neurogenic bladder (1,6). They are usually located along the lateral walls of the bladder, which is the area most prone to deformity caused by elevated intravesical pressure (1). Clean intermittent catheterization (CIC) is commonly prescribed in patients with high post-void residual (PVR) volumes of urine in the bladder.

Robot-assisted laparoscopic prostatectomy (RALP) is known to carry a risk of postoperative stress urinary incontinence as a sequela of the procedure (7,8). However, in patients with preexisting neurological injuries before surgery, postoperative management of voiding dysfunction can be more complex. In neurogenic bladder cases, PVRs may decrease after RALP because the sphincter will no longer be present.

However, in this case, the patient did not require CIC before RALP. Years later, he developed very large diverticulum causing significant morbidity requiring CIC and ultimately requiring definitive management with diverticulectomy. There have been three previous reports in which patients presented with bladder outlet obstruction and lower urinary tract symptoms and were found to have both prostate cancer (PCa) and large bladder diverticula. Sequential, combined, surgical treatments

Correspondence: Asher Mandel MD, The Milton and Carroll Petrie Department of Urology at the Icahn School of Medicine at Mount Sinai, New York, USA

E-mail: asher.mandel@mountsinai.org **ORCID-ID:** orcid.org/0000-0001-8529-6792

Received: 18.09.2023 **Accepted:** 24.02.2024

Cite this article as: Mandel A, Kolanukuduru KP, Choudhary MK, Bhardwaj S, Wagaskar V, Reddy A, Tewari A. Robot Assisted Bladder Diverticulectomy Seven Year After Radical Prostatectomy.



for both conditions have been shown to be safe (9,10). To our knowledge, there has been no previous documentation of robotic diverticulectomy performed several years after RALP. Here, we explore such a case and its clinical outcomes.

Case Presentation

This is a 77-year-old male, with a remote history of cervical spine injury from a bicycle accident, as well as a history of PCa status post RALP seven years prior, who presented to our clinic complaining of chronic UTIs, which led to hospital admission for urosepsis. He was subsequently found to have highly elevated PVRs and bladder diverticula. Of note, magnetic resonance imaging during the pre-RALP workup reported only small diverticula. Urodynamic studies from the past year show a maximum flow rate of 2.8, voided volume of 50 cc, PVR of 360 cc, and pressure readings consistent with DSD. He had previously experienced intraperitoneal perforation of his bladder at an outside hospital, from which he recovered well with conservative management. However, it could not be visualized with cystoscopy and was considered possibly walled off. At this time, it was considered whether the diverticulum seen on computed tomography scan (Figure 1) was a true diverticulum or a contained perforation. Cystoscopy revealed diffuse inflammatory changes on the posterior and right lateral walls of the bladder. Severe trabeculations and numerous small diverticula were observed. Figure 2 shows images from the cystogram performed at that time, which shows a large volume of urine retained in the diverticulum during the voiding phase. At follow-up appointments, he requested definitive management. He was scheduled for robotic bladder diverticulectomy.

Operative Report Summary

On the day of surgery, the patient was taken to the operating room and induced under general anesthesia. He was positioned in the supine position in Trendelenburg. A cystoscope was

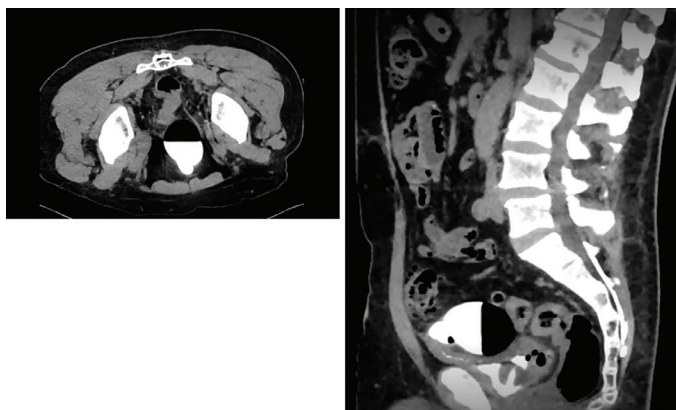


Figure 1. Axial and sagittal CT images showing the diverticulum's anterior and superior position along the bladder wall

CT: Computed tomography

used to try to identify the main diverticulum, but this was not successful.

We proceeded to identify the diverticulum using the robot. He created a circular mucosal incision around the diverticular neck, dissected posteriorly, and then progressed laterally and anteriorly (Figure 3). The specimen (diverticulum) was retrieved and manually examined before being sent for surgical pathology. The bladder was closed in 2 layers. 2-0 Stratafix suture was used to close the detrusor and mucosal layers, with careful approximation of the mucosal edges. Imbricating sutures were placed using 2-0 V-loc suture. The bladder was distended with 300 mL, and a watertight closure was confirmed. A JP drain was inserted, and the urethral catheter was left in place.

The patient tolerated the procedure well and was accompanied to the recovery room in a stable condition. The estimated blood loss was 50 mL. The patient was discharged on hospital day 3 with a Foley catheter. A cystogram performed 2 weeks after surgery showed no evidence of diverticulum.

Pathologic Examination

The diagnosis was confirmed by pathological assessment. Histopathological examination showed a pouch-like structure lined with urothelium. The underlying subepithelial tissue showed well-organized, thickened muscularis mucosae, thus distinguishing this entity from a pseudodiverticulum of the bladder.

Discussion

The unusual features of this case include the enormous size and atypical location (at the dome) of the bladder diverticulum. Despite the patient using CIC preoperatively, he was unable to empty his bladder sufficiently because of the large volume of urine trapped in the diverticulum, as was seen on the voiding phase of his cystogram. The patient's previous bladder perforation made it difficult to assess from imaging alone whether this abnormal pouch was a contained perforation or a true diverticulum. The location at the dome points toward the contained perforation. However, intraoperatively, there were visual features of the tissue that pointed more toward the

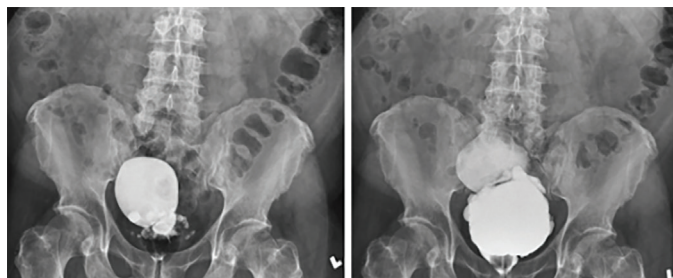


Figure 2. Cystogram images showing filling (right) and voiding (left) phases

diverticulum and not a contained perforation. For example, the neck of the diverticulum was smooth and circular. In the case of a contained perforation, a larger, irregular neck is usually observed. The walls of the diverticulum itself were smooth and regular. Perforations are usually thickened and irregular. Finally, there were no adhesions attached to the structure, which are commonly seen in perforations. For these reasons, the etiology was considered to be bladder diverticulum secondary to neurogenic bladder and not due to a contained perforation. The diagnosis was confirmed by pathological assessment.

The lesson to be learned from this case is that patients with underlying neurogenic bladder, who undergo RALP, may have a change in their bladder function that may not follow the usual predicted pattern. This patient was never found to have bladder neck contracture or lower urinary tract stricture. Additionally, he did not require CIC before he underwent RALP. This suggests

that the pathophysiological mechanisms causing the diverticula likely continued or might have even been enhanced by RALP. The most likely pathophysiological mechanism underlying the development of the larger diverticulum is DSD secondary to the neurogenic bladder. One may expect that RALP relieved the dyssynergia by compromising the integrity of the sphincter. However, the sequelae developed anyway. This case suggests that close monitoring of patients with preexisting neurogenic bladder could be beneficial because bladder function evolves after radical prostatectomy. Post-RALP uroflowmetry and urodynamics are reasonable tests for complex cases. Providers may carry a low threshold to start CIC when PVRs are elevated or in cases of compromised bladder voiding efficiency (11).

Ethics

Informed Consent: Informed consent was obtained from the patient.

Authorship Contributions

Surgical and Medical Practices: V.W., A.R., A.T., Concept: A.M., K.P.K., M.K.C., A.T., Design: A.M., K.P.K., M.K.C., S.B., V.W., A.R., A.T., Data Collection or Processing: A.M., K.P.K., Analysis or Interpretation: A.M., K.P.K., M.K.C., S.B., V.W., A.R., A.T., Literature Search: A.M., K.P.K., M.K.C., S.B., Writing: A.M., K.P.K., M.K.C., S.B., V.W., A.R., A.T.

Conflict of Interest: No conflict of interest was declared by the authors.

Financial Disclosure: The author declared that this study received no financial support.

References

- Halaseh SA, Leslie SW. Bladder Diverticulum. 2023 May 30. In: StatPearls [Internet]. Treasure Island (FL): StatPearls Publishing; 2023 Jan.
- Voskuilen CS, Seiler R, Rink M, Poyet C, Noon AP, Roghmann F, Necchi A, Aziz A, Lavollé A, Young MJ, Marks P, Saba K, van Rhijn BWG, Fransen van de Putte EE, Ablat J, Black PC, Sosnowski R, Dobruch J, Kumar P, Jallad S, Catto JWF, Xylinas E, Hendricksen K; Young Academic Urologists' Working Group on Urothelial Carcinoma of the European Association of Urology. Urothelial Carcinoma in Bladder Diverticula: A Multicenter Analysis of Characteristics and Clinical Outcomes. *Eur Urol Focus* 2020;6:1226-1232.
- Bacsu CD, Chan L, Tse V. Diagnosing detrusor sphincter dyssynergia in the neurological patient. *BJU Int* 2012;109(Suppl 3):31-34.
- Feloney MP, Leslie SW. Bladder Sphincter Dyssynergia. 2022 Nov 28. In: StatPearls [Internet]. Treasure Island (FL): StatPearls Publishing; 2023 Jan.
- Leslie SW, Tadi P, Tayyeb M. Neurogenic Bladder and Neurogenic Lower Urinary Tract Dysfunction. 2023 May 30. In: StatPearls [Internet]. Treasure Island (FL): StatPearls Publishing; 2023 Jan.
- Sacco E, Prayer-Galetti T, Pinto F, Fracalanza S, Betto G, Pagano F, Artibani W. Urinary incontinence after radical prostatectomy: incidence by definition, risk factors and temporal trend in a large series with a long-term follow-up. *BJU Int* 2006;97:1234-1241.
- Trofimenko V, Myers JB, Brant WO. Post-Prostatectomy Incontinence: How Common and Bothersome Is It Really? *Sex Med Rev* 2017;5:536-543.

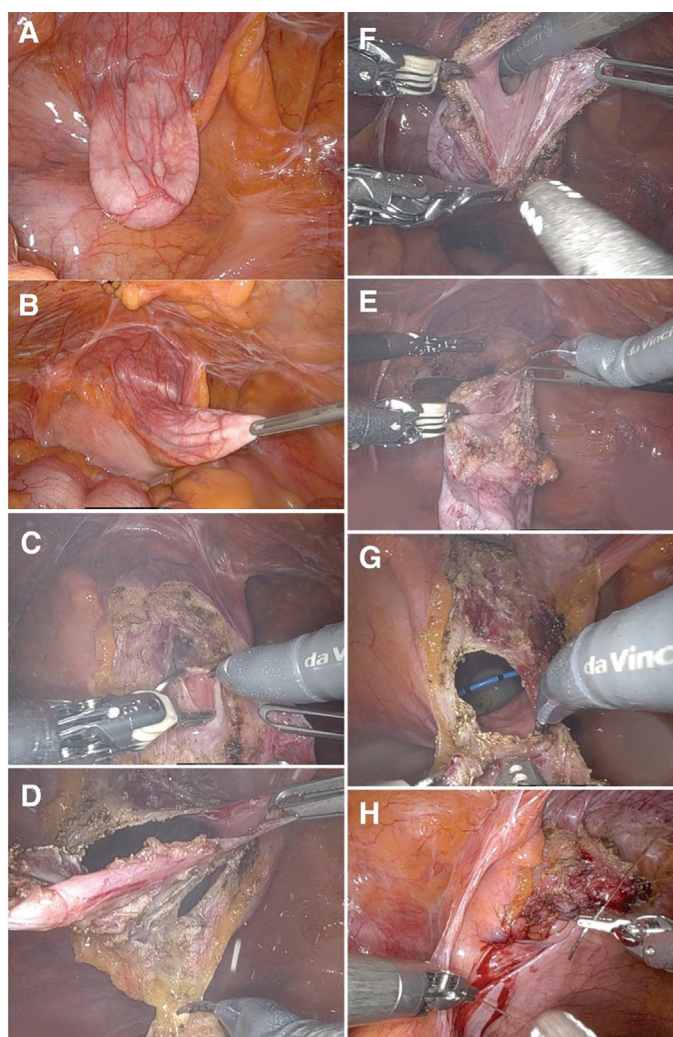


Figure 3. Intraoperative Images. A: intraperitoneal appearance of diverticulum; B: diverticulum on tension; C: Incision and dissection to mucosa; D: En bloc resection; Figure E: Specimen; F: Specimen with robotic arm inside defect; Figure G: Neck of diverticulum (Foley and stents seen); Figure H: Bladder reconstruction

8. Loughlin KR, Prasad MM. Post-prostatectomy urinary incontinence: a confluence of 3 factors. *J Urol* 2010;183:871-877.
9. Yoshimura I, Uchida H, Nakayama A, Takatama K, Yoshida T. Robot-assisted bladder diverticulectomy sequentially followed by robot-assisted radical prostatectomy: a case series. *J Robot Surg* 2019;13:227-230.
10. Ploumidis A, Skolarikos A, Sopilidis O, Chalikopoulos D, Alivizatos G, Wiklund P. Sequential robotic-assisted bladder diverticulectomy and radical prostatectomy. Technique and review of the literature. *Int J Surg Case Rep* 2013;4:81-84.
11. Chapple C, Abrams P, Lam T, Mangera A, Belal M, Curtis C, Emkes J, Hillery S, Irwin K, Logan K, Weston P, Yates A. A consensus statement on when to start clean intermittent self-catheterization: An untapped resource? *Neurourol Urodyn* 2024;43:459-463.