



# Intraductal Carcinoma of the Prostate

## Prostatın İntraduktal Karsinomu

Mustafa Fuat Açıklalın

Eskişehir Osmangazi University Faculty of Medicine, Department of Pathology, Eskişehir, Turkey

### Introduction

Intraductal carcinoma of the prostate (IDC-P) is a term that refers to prostatic adenocarcinoma extending into and proliferating within preexisting prostatic ducts or acini (1). It is often associated with high-grade invasive prostatic adenocarcinoma and is also an adverse prognostic marker (1,2,3).

The histologic differential diagnosis of IDC-P on prostate needle biopsy includes high-grade prostatic intraepithelial neoplasia (HGPIN), invasive cribriform prostatic adenocarcinoma, prostatic ductal adenocarcinoma, and urothelial carcinoma extending into prostatic ducts. Diagnostic reproducibility is low in the category of intraductal lesions of the prostate (4) whereas, accurate diagnosis is crucial for patient management. When IDC-P is accompanied by invasive carcinoma, it is associated with higher grade and higher stage cancer. Isolated IDC-P (IDC-P unaccompanied by invasive cancer) on needle biopsy is generally associated with high-grade invasive prostatic adenocarcinoma on subsequent radical prostatectomy (2,4). IDC-P requires either definitive therapy or prompt rebiopsy. In contrast, HGPIN is considered a preneoplastic lesion; its presence does not require definitive therapy and in limited quantities, does not require rebiopsy. If urothelial carcinoma extending into prostatic ducts is identified on needle biopsy, radical cystoprostatectomy is recommended. Usual (acinar) prostatic adenocarcinoma and prostatic ductal adenocarcinoma are treated in the same manner and require definitive treatment.

Histologically, IDC-P is characterized by malignant epithelial cells filling and expanding nonneoplastic prostatic ducts and acini with at least partial preservation of an identifiable basal cell layer. Five patterns have been described: solid, dense cribriform, loose cribriform, micropapillary, and flat (rare). There is often marked nuclear atypia and frequent mitotic activity or comedonecrosis.

IDC-P and HGPIN share many cytological features, such as nuclear enlargement and hyperchromasia, and prominent nucleoli (4). Furthermore, both lesions can show loose cribriform and micropapillary patterns. In contrast to IDC-P, HGPIN lacks solid or

dense cribriform patterns, rarely have comedonecrosis, and lacks marked pleomorphism. In HGPIN, very focal comedonecrosis may be seen, but nonfocal comedonecrosis is not observed (1). The outlines of prostatic ducts with HGPIN are usually smooth with rounded contours, in contrast to irregular outlines in IDC-P (5).

The morphologic distinction between IDC-P and cribriform prostatic acinar adenocarcinoma can be difficult. Cribriform prostatic acinar adenocarcinoma lacks the branching glands often seen in IDC-P and the identification of basal cells on immunostaining for basal cell markers serves to distinguish IDC-P from invasive prostatic carcinoma.

Intraductal spread of urothelial carcinoma is an important mimicker of solid IDC-P. Solid IDC-P is often associated with cribriform patterns elsewhere, which is not seen with intraductal spread of urothelial carcinoma (4). Greater nuclear pleomorphism, increased mitotic activity, and stromal inflammation favor intraductal spread of urothelial carcinoma (1). Furthermore, in intraductal spread of urothelial carcinoma, tumor cells are negative for prostate-specific antigen and prostate-specific acid phosphatase, and usually positive for p63 and high-molecular-weight cytokeratin.

The cribriform pattern of prostatic ductal adenocarcinoma is most likely to be confused with IDC-P. Prostatic ductal adenocarcinoma has cribriform glands with large, slit-like lumina, tall columnar tumor cells, papillary fronds with true vascular cores and usually lacks basal cells.

In conclusion, the differential diagnosis of intraductal lesions of the prostate on core needle biopsy is not always straightforward, but because of both therapeutic and prognostic implications, accurate diagnosis is crucial.

### Keywords

Intraductal carcinoma, prostate, differential diagnosis

### Anahtar Kelimeler

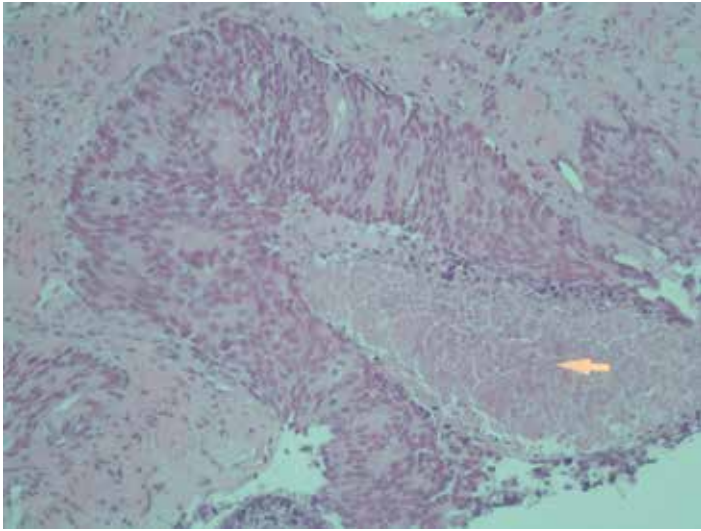
İntraduktal karsinom, prostat, ayırıcı tanı

### Ethics

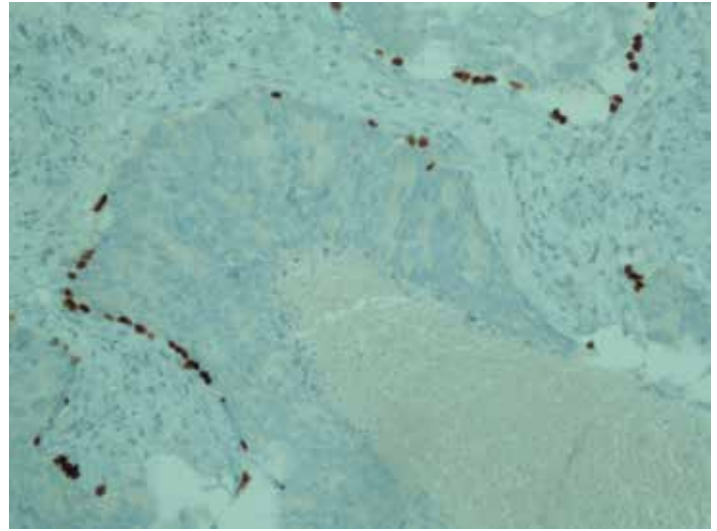
Peer-review: Internal peer-reviewed.

### Correspondence

Mustafa Fuat Açıklalın MD, Eskişehir Osmangazi University Faculty of Medicine, Department of Pathology, Eskişehir, Turkey  
Phone: +90 222 239 29 79-4533 E-mail: acikalın@ogu.edu.tr Received: 01.08.2016 Accepted: 09.08.2016



**Figure 1.** Intraductal carcinoma of the prostate showing comedonecrosis in a large duct (H&E x200)



**Figure 2.** The large duct shows the presence of basal cells on immunostaining for p63 (x200)

## References

1. Magers M, Kunju LP, Wu A. Intraductal carcinoma of the prostate: morphologic features, differential diagnoses, significance, and reporting practices. *Arch Pathol Lab Med* 2015;139:1234-1241.
2. Robinson BD, Epstein JI. Intraductal carcinoma of the prostate with out invasive carcinoma on needle biopsy: emphasis on radical prostatectomy findings. *J Urol* 2010;184:1328-1333.
3. Kimura K, Tsuzuki T, Kato M, Saito AM, Sassa N, Ishida R, Hirabayashi H, Yoshino Y, Hattori R, Gotoh M. Prognostic value of intraductal carcinoma of the prostate in radical prostatectomy specimens. *Prostate* 2014;74:680-687.
4. Wobker SE, Epstein JI. Differential Diagnosis of Intraductal Lesions of the Prostate. *Am J Surg Pathol* 2016;40:67-82.
5. Divatia MK, Ro JY. Intraductal carcinoma of the prostate gland: recent advances. *Yonsei Med J* 2016;57:1054-1062.