

# A Large Bladder Tumor During Pregnancy: Twin Challenge

✉ Gagandeep Singh<sup>1</sup>, ✉ Sunil Chawla<sup>2</sup>, ✉ Priyaranjan Nandy<sup>1</sup>, ✉ Meenakshi Rajput<sup>2</sup>

<sup>1</sup>Command Hospital, Clinic of Urology, Udhampur, India

<sup>2</sup>Command Hospital, Clinic of Obstetrics and Gynaecology, Udhampur, India

## Abstract

Urological malignancies during pregnancy are extremely rare, affecting about 13 in 1,000,000 pregnancies. Common signs of urological malignancies especially bladder tumors such as hematuria, urgency, lower abdominal pain, may be attributed to the pregnancy. Combined with the hesitancy to undergo imaging, these overlapping symptoms may result in delayed diagnosis. We report the case of a young female who was incidentally detected to have a large bladder tumor during the second trimester of her pregnancy. She underwent a transurethral resection of the bladder tumour during 26<sup>th</sup> week of pregnancy and histopathology was suggestive of a high-grade lamina invasive urothelial carcinoma. Her pregnancy continued till 34 weeks, when she delivered a 2.14 kg healthy female child. Restaging transurethral resection of the bladder tumour done four days after delivery was negative for malignancy. She is presently on intravesical Bacillus Calmette-Guérin therapy. Although a rare occurrence, treatment of bladder malignancies during pregnancy requires a multidisciplinary approach while taking into consideration the mother's health, neonatal outcome and the perspective of both parents.

**Keywords:** Bladder tumour, pregnancy, intravesical therapy

## Introduction

Malignant tumors during pregnancy are a rarity with the overall incidence being approximately 2.35/10,000 (1) and the commonest are malignant melanomas (2.8/1,000), cervix (1/2,200), breast (1/3,000) and lymphomas (1/6,000) (2,3). Urological malignancies during pregnancy are extremely rare, affecting about 13 in 1,000,000 pregnancies (4). Common signs of urological malignancies especially bladder tumors such as hematuria, urgency, lower abdominal pain, may be attributed to the pregnancy. Combined with the hesitancy to undergo imaging, these overlapping symptoms may result in delayed diagnosis.

The first reported case of bladder carcinoma in pregnancy was by Waser (5) in 1927. Since then, less than 50 cases have been reported in literature (6). Due to the rarity of the presentation, there are no standard guidelines for the subject. The treatment hence needs to be tailored in consultation with the Obstetrician and family.

## Case Report

32-yr-old lady, an antenatal case, G3P1A1L1, presented at 26 weeks period gestation with c/o intermittent, gross, total,

painless hematuria for 3 months. There was no history of tobacco consumption in any form with no other significant past medical or surgical history. Ultrasound revealed a single live intrauterine fetus of 24 weeks with mild dilatation of the pelvicalyceal system on the right side. There was a 4.3x4.7x5.2 cm echogenic mass lesion noted along the right posterolateral wall of urinary bladder with significant vascularity within. Contrast-enhanced magnetic resonance imaging of pelvis confirmed a 4.3x4.5x4.7 cm sized mass lesion seen arising from the right posterolateral wall of urinary bladder. The lesion was isointense on T1WI, mildly hyperintense on T2WI, STIR (Figure 1) and showed intense post contrast enhancement (Figure 2). There appeared to be focal disruption of the hypointense line on T2WI in the bladder underneath the lesion - likely representing invasion into the deep muscle. A prominent vessel was seen to enter the lesion from its base. No extension of the lesion beyond the bladder wall was noted. The right ureterovesical junction did not appear to be involved. Perivesical fat was normal. A single live intrauterine fetus was seen corresponding to 25 weeks period of gestation.

After discussing the case with both parents and the obstetrician and counseling about the risk to the fetus, the patient gave informed, written consent and underwent bipolar transurethral resection of the bladder tumour (TURBT) under regional

**Correspondence:** Gagandeep Singh MD, Command Hospital, Clinic of Urology, Udhampur, India

**Phone:** +91 9764610900 **E-mail:** gagan150582@gmail.com **ORCID-ID:** orcid.org/0000-0002-3567-5353

**Received:** 07.06.2021 **Accepted:** 25.04.2022

**Cite this article as:** Singh G, Chawla S, Nandy P, Rajput M. A Large Bladder Tumor During Pregnancy: Twin Challenge. J Urol Surg, 2022;9(2):146-149.

©Copyright 2022 by the Association of Urological Surgery / Journal of Urological Surgery published by Galenos Publishing House.



anaesthesia. Intraoperative finding - large 5x5 cm frondy growth with broad base and foci of calcification over the right lateral wall away from the right ureteric orifice. Histopathology revealed high grade papillary urothelial neoplasm with evidence of invasion of underlying lamina propria; single focus of deep muscle seen in the TURBT specimen did not show definite evidence of invasion. Extensive pleomorphism and calcification were seen, however these cells were negative for Vimentin on immunohistochemistry. The case was discussed with the couple and it was decided to defer Restaging TURBT till delivery.

Pregnancy was continued until 34 weeks in view of intrauterine growth retardation. She underwent spontaneous normal delivery and delivered a 2.14 kg healthy female child. She then underwent restaging TURBT under regional anesthesia 4 days after the delivery. Intraop finding - no recurrence, deep muscle biopsies were taken from the scar site. Histopathology the biopsy result was negative for malignancy. Thereafter, in view of high-risk bladder cancer, the patient was started on intravesical therapy - 80 mg intravesical Bacillus Calmette-Guérin (BCG) as per the SWOG regime 4 weeks after the surgery. She has been on regular therapy and follow-up as per National Comprehensive Cancer Network (NCCN) guidelines and is recurrence free at 1 yr follow-up (7).

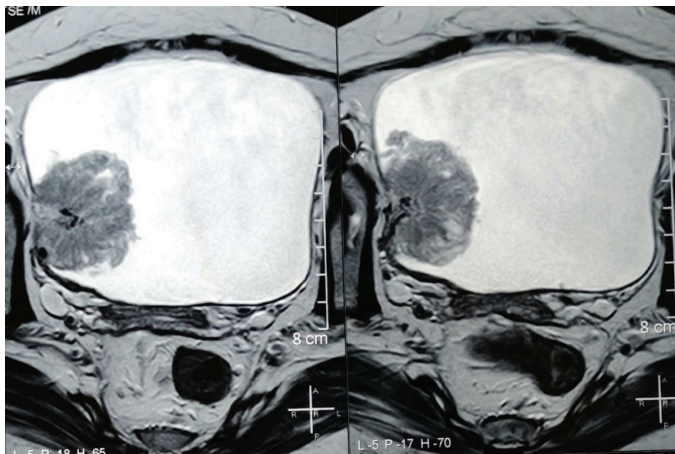


Figure 1. T1 and T2 WI of bladder tumour

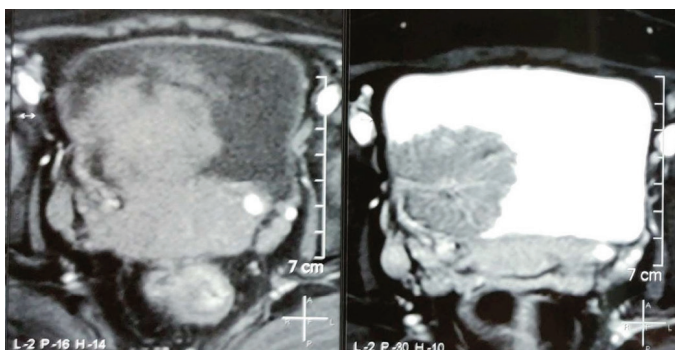


Figure 2. Intense post contrast enhancement

## Discussion

Urological malignancies in pregnancy are a rarity, with an approximate incidence of 0.0013%. The commonest tumors are renal tumors, followed by bladder tumors and finally pheochromocytomas. Bladder tumors during pregnancy have been described since 1927, with transitional cell carcinoma (TCC) being the most common (70%) (6). The objective of this case report is to highlight the multidisciplinary care and selective approach involved in the management of bladder cancers, which present during pregnancy.

It has long been debated in the literature whether pregnancy plays a potential "protective" or "increased risk" role in the occurrence and spread of cancer. The antigens of the fetus are tolerated by the immune system of the mother. The point to be considered is whether this state of tolerance of the immune system of the mother "protects or potentiates" the development of cancer. Some theories state that pregnancy is a state of immunosuppression to tolerate the antigens of the fetus, however, this state of immunosuppression is specific only to fetal antigens as pregnant ladies mount an adequate immune response to all other antigens: Viral, bacterial, helminthic or neoplastic.

In the general population, TCC account for more than 90% of bladder cancers and superficial cancers account for more than 70% of newly diagnosed bladder TCCs. Painless hematuria is the commonest presentation in bladder tumors (80-90%). In pregnant women, however, the presentation is often delayed as urinary symptoms in pregnancy are often ignored and hematuria mistaken for vaginal bleeding. Thus, unwarranted obstetric examination is often carried out in these patients to rule out causes such as placenta praevia and abruptio placenta (8). When correctly identified as hematuria, complete evaluation should be conducted and bladder cancer should be considered in the differential diagnosis. Cystitis is the most common cause of hematuria in pregnancy (9), but hematuria not responding to antibiotic warrants complete detailed evaluation. Ultrasonography of the bladder is useful, but in no way diagnostic, as half of the cases were identified on ultrasonography. Flexible cystoscopy under local anesthesia is an extremely useful option in evaluating hematuria in pregnancy.

Imaging during pregnancy is also a dilemma. Computed tomography scan is contraindicated due to the well-known factor of radiation exposure. Hence, magnetic resonance imaging is the imaging modality of choice for the evaluation of bladder tumors during pregnancy.

The factors, which decide the treatment are the trimester of pregnancy at which the patient has presented and the stage of malignancy (10). Patients are stratified into low,

intermediate and high-risk groups based on the AUA Risk Stratification criteria for non-muscle invasive bladder cancer (NMIBC). Thereafter, they may be managed as per the NCCN Guidelines Version 3.2021 for NMIBC (7). Options for intravesical therapy include gemcitabine, mitomycin and BCG. There is a high risk of local vesical irritative symptoms, which however is mild and transient. Systemic side effects though rare may range from mild symptoms to severe illness (e.g. sepsis, arthritis). There are only two case reports of intravesical therapy during pregnancy (11,12) with normal fetal outcomes reported in both. Due to the known embryotoxicity of live vaccines like BCG and systemic chemotherapy like mitomycin, great caution needs to be exercised in the use of these agents during pregnancy (13). A more pragmatic approach would be to continue the patient on 3 monthly follow-up cystoscopy and defer the use of intravesical therapy till termination of pregnancy. In patients with muscle-invasive bladder carcinoma, with or without lymph node involvement, neoadjuvant platinum-based chemotherapy followed by radical cystectomy is the treatment of choice (7). The deciding factor whether to proceed with the termination of pregnancy and further treatment or to initiate chemotherapy during pregnancy or after completion of pregnancy would be the trimester of pregnancy. Complications of chemotherapy during pregnancy, such as intrauterine ototoxicity (14), intrauterine growth retardation and pre-term contractions, should be discussed with the patient. It is advisable to perform the radical cystectomy 3-4 weeks after delivery to minimize the increased risk of blood loss due to pregnancy induced pelvic congestion. In patients with metastatic bladder cancer, palliative chemotherapy is the only treatment option.

Except for the early first trimester, when there is a high risk of miscarriage, TURBT can be performed at any time during the surgery. Spinal anesthesia is considered a safer alternative than general anesthesia. A bipolar technique with a lesser incidence of bladder perforation and electrolyte imbalance is a better option than the monopolar technique. The decision for normal vaginal delivery or cesarean section should be based on obstetric and fetal factors. Theoretical risks of obstructed labor due to large bladder tumour, the dissemination of the tumor during the passage of the fetus through the birth canal, injury to the bladder during cesarean section should also be taken into consideration. Treatment goals should include postponement of delivery beyond 35-37 weeks of gestation, whenever possible, to safeguard neonatal outcome (14).

## Conclusion

Although a rare occurrence, bladder malignancy should be considered a possible diagnosis when pregnant women present with symptoms such as gross hematuria. The trimester at

which the lady presents and the stage of the tumor are the two most important determinants of treatment. Surgery can be offered safely in all three trimesters. Due to limited experience and high risk of adverse fetal outcomes, intravesical therapy should be postponed until after delivery and patients should be managed with regular cystoscopy follow up after the TURBT. To summarize, the treatment of bladder malignancies during pregnancy requires a multidisciplinary approach while taking into consideration the mother's health, neonatal outcome and the perspective of both parents.

## Ethics

**Informed Consent:** Informed consent was obtained.

**Peer-review:** Externally peer-reviewed.

## Authorship Contributions

Surgical and Medical Practices: G.S., S.C., M.R., Concept: G.S., S.C., M.R., Design: S.C., Data Collection or Processing: P.N., Analysis or Interpretation: P.N., Literature Search: G.S., P.N., Writing: G.S.

**Conflict of Interest:** No conflict of interest was declared by the authors.

**Financial Disclosure:** The authors declared that this study received no financial support.

## References

1. Kennedy S, Yudkin P, Greenall M. Cancer in pregnancy. *Eur J Surg Oncol* 1993;19:405-407.
2. Doll DC, Ringenberg QS, Yarbrow JW. Management of cancer during pregnancy. *Arch Intern Med* 1988;148:2058-2064.
3. Donegan WL. Cancer and pregnancy. *CA Cancer J Clin* 1983;33:194-214.
4. Smith LH, Danielsen B, Allen ME, Cress R. Cancer associated with obstetric delivery: results of linkage with the California cancer registry. *Am J Obstet Gynecol* 2003;189:1128-1135.
5. Waser B. VI. Blasenkarzinom in der Schwangerschaft. *Monatsschr Geburtsh Gynäkol* 1927;77:423-428.
6. Rojas PA, González C, Mendez GP, Majerson A, Francisco IFS. Bladder squamous cell carcinoma in a pregnant woman: case report and review of the literature. *BMC Urol* 2021;21:4.
7. National Comprehensive Cancer Network. Bladder Cancer Ver 3, 2021.
8. Mitra S, Williamson JG, Bullock KN, Arends M. Bladder cancer in pregnancy. *J Obstet Gynaecol* 2003;23:440-442.
9. Choate JW, Theide HA, Miller HC. Carcinoma of bladder in pregnancy: report of three cases. *Am J Obstet Gynecol* 1964;90:526-530.
10. Maggen C, Linssen J, Gziri MM, Zola P, Cardonick E, de Groot CJM, Garcia AC, Fruscio R, Drochytsek V, Van Calsteren K, Albersen M, Amant F; International Network on Cancer, Infertility and Pregnancy (INICIP). Renal and Bladder Cancer During Pregnancy: A Review of 47 Cases and Literature-based Recommendations for Management. *Urology* 2021;151:118-128.
11. Shrotri KN, Ross GC. Bladder carcinoma presenting during twin pregnancy. *J Obstet Gynaecol* 2008;28:750-751.

12. Wax JR, Ross J, Marotto L, Pinette MG, Blackstone J. Nonbilharzial bladder carcinoma complicating pregnancy--treatment with bacille Calmette-Guerin. *Am J Obstet Gynecol* 2002;187:239-240.
13. Boike GM, Deppe G, Young JD, Malone Jr JM, Malviya VK, Sokol RJ. Chemotherapy in a pregnant rat model. 1. Mitomycin-C: pregnancy-specific kinetics and placental transfer. *Gynecol Oncol* 1989;34:191-194.
14. Amant F, Vandenbroucke T, Verheecke M, Fumagalli M, Halaska MJ, Boere I, Han S, Gziri MM, Peccatori F, Rob L, Lok C, Witteveen P, Voigt JU, Naulaers G, Vallaes L, Van den Heuvel F, Lagae L, Mertens L, Claes L, Van Calsteren K; International Network on Cancer, Infertility, and Pregnancy (INCIP). Pediatric Outcome after Maternal Cancer Diagnosed during Pregnancy. *N Engl J Med* 2015;373:1824-1834.