

# Torsion of the Testis or Appendix Testis? An Analysis of Presentation, Management and Outcome of Acute Scrotum in Children

✉ Raphael Müller<sup>1+</sup>, ✉ Andrea Katharina Lindner<sup>1+</sup>, ✉ Christoph Mayerhofer<sup>2</sup>, ✉ Gregor Laimer<sup>3</sup>, ✉ Friedrich Aigner<sup>3</sup>,  
✉ Christian Radmayr<sup>1</sup>

<sup>1</sup>Medical University Faculty of Medicine, Department of Urology, Innsbruck, Austria

<sup>2</sup>Medical University Faculty of Medicine, Department of Paediatrics I, Innsbruck, Austria

<sup>3</sup>Medical University Faculty of Medicine, Department of Radiology, Innsbruck, Austria

+Equally contributing first authors

## What's known on the subject? and What does the study add?

Acute scrotum in children presents as a paediatric urological emergency. It is mainly caused by testicular torsion (TT), leaving a time window of only a few hours to irreversible damage, or in up to 50% by torsion of the appendix testis (ATT). TT requires immediate surgery, whereas ATT can be managed conservatively. Rate of surgical exploration revealing no TT is high when no clinical score criteria was applied. Aim of the study therefore was to establish clinical predictors to distinguish between TT and ATT, preventing unnecessary surgery. Our data promote that additional to an absent cremasteric reflex, testicular swelling and high-riding testis, age >10 years and symptom onset in the night support diagnosis of TT. The primary clinical approach should therefore remain and not be replaced by alternative indicators or color Doppler ultrasonography.

## Abstract

**Objective:** To elaborate clinical predictors to safely distinguish between testicular torsion (TT) and the appendix testis torsion (ATT) and emphasize a diagnostic algorithm to reduce unnecessary exploration rates. TT requires prompt assessment and surgical intervention to achieve tissue function. Torsion of the ATT is the most common differential diagnosis, which can usually be treated conservatively. Colour-Doppler ultrasonography (CDUS) remains controversial for detection of TT.

**Materials and Methods:** Data were retrospectively collected from patients under the age of 20 years admitted to our hospital with acute scrotal pain from 2017 to 2020. The main outcome measures were the onset of symptoms, clinical criteria of absent cremasteric reflex, testicular swelling and high-riding testis, perfusion in CDUS and pathology found during scrotal exploration.

**Results:** Seventy-one patients met the inclusion criteria. Mean age was 10.6 years. 53.2% were diagnosed with TT, 41.6% with ATT, 1.3% with epididymitis and in 3.9%, no pathology was found. Patients with TT were significantly older compared to patients with ATT ( $p < 0.004$ ). TT showed a more frequent onset of symptoms during night-time ( $p < 0.006$ ). 87.8% of TT had two of the three defined clinical criteria, compared with 18.8% of ATT ( $p < 0.001$ ). The limitations of this study were the retrospective design and interobserver variability.

**Conclusion:** Our findings support the safety and importance of clinical criteria to distinguish between TT and ATT. CDUS should not supersede clinical evaluation. The decision to surgically explore should be made on clinical grounds as a standard approach for assessing acute scrotum.

**Keywords:** Acute scrotal pain, acute scrotum, testicular torsion, torsion of the appendage testis, scrotal elastography

**Correspondence:** Raphael Müller MD, Medical University Faculty of Medicine, Department of Urology, Innsbruck, Austria

**Phone:** + 43 512 504 24875 **E-mail:** raphael.mueller@tirol-kliniken.at **ORCID-ID:** orcid.org/0000-0001-8725-1512

**Received:** 03.03.2022 **Accepted:** 23.05.2022

**Cite this article as:** Müller R, Lindner AK, Mayerhofer C, Laimer G, Aigner F, Radmayr C. Torsion of the Testis or Appendix Testis? An Analysis of Presentation, Management and Outcome of Acute Scrotum in Children. J Urol Surg, 2023;10(1):49-54.

©Copyright 2023 by the Association of Urological Surgery / Journal of Urological Surgery published by Galenos Publishing House.



## Introduction

Testicular torsion (TT) is a pediatric urological emergency, leaving a time window of a few hours until irreversible damage occurs in the affected testis (1). In males younger than 18 years, the annual incidence of TT is 3.8% (2,3). The age distribution shows two peaks, one in the perinatal period and one in adolescence (4). In 5–25%, TT as the underlying cause of acute scrotum (5), requires quick surgical exploration within eight hours the maximum to avoid loss of testicular tissue (6). Clinical parameters indicative of TT include sudden onset of pain, high or horizontal position of the testicle, swelling, and missing cremasteric reflex (5,7). The absent cremasteric reflex has been described to be specific for TT (8). An appendix testis can be found in 83% of male individuals (9) and appendix testis torsion (ATT) grants for almost half of the boys presenting with acute scrotal pain (10), with an age peak of 7 to 12 years (11). ATT is a self-limiting condition treated primarily conservative including bed rest, scrotal elevation and non-steroidal anti-inflammatory drugs. Surgery should only be performed if the clinical differentiation from TT is uncertain. It has been shown that the rate of surgical exploration revealing no pathology was very high (86%) when neither systematic clinical criteria score, nor further diagnostics were applied (5). However, due to the intensity of pain as well as the young age, clinical examination might be difficult or inconclusive (12).

Colour-Doppler ultrasonography (CDUS) to distinguish TT from ATT is discussed controversially. Often a hyperperfusion of the upper pole is seen in case of ATT. Differential diagnostic an orchitis should be considered if the whole testicle shows an increased blood flow. Its availability and cost-efficiency in synopsis with a high rate of sensitivity (70–90%) and specificity (98–100%) leaves CDUS as the standard imaging method for acute scrotum (13). Limitations are still given, the examiner dependency with a high inter- and even intraobserver variability (14), leading to waiving of surgical exploration, can result in inevitable testicular loss (15). Additionally, the persistence of arterial flow was found in 24% patients with TT and therefore not really a reliable parameter (16).

The aim of our retrospective single-centre study was to elaborate clinical predictors to distinguish between the presence of TT and ATT and to utilize a diagnostic algorithm to reduce unnecessary surgical interventions.

## Materials and Methods

This is a retrospective observational study based on a retrospective analysis of the uro-paediatric database of our department. Research study was performed in accordance with the Helsinki declaration and institutional ethical standards. The project was approved by the local medical research ethics committee with the number 1393/2020.

## Patients

All patients younger than 20 years who presented at the urological emergency department with acute scrotal pain between 2017 and 2020 were included. History was taken concerning the onset and duration of pain, local symptoms, history of trauma and other urological medical issues, such as inguinal surgery. All patients were thoroughly examined by a consultant. Three main clinical symptoms were evaluated at admission, including acute onset of scrotal pain, position of the testicle and presence of cremasteric reflex. CDUS was performed during day time department hours by a radiologist using a Hitachi Ascendus ultrasound machine with a 13-Mhz linear probe, otherwise ultrasound was carried out by a certified urologist with experience in pediatric scrotal sonography. Imaging defined normal-, hyper- or hypoperfusion, as well as elasticity, when applicable. Based on clinical criteria, additional CDUS findings - underpin the suspicion of TT - strengthened the indication for surgical exploration. When clinical criteria were suspicious of TT and CDUS was not, surgical exploration was mandatory. In all cases, concordant with the standard approach at our institution, it was of great importance that no time delay to surgery because of performing CDUS occurred. Final diagnosis was based on the results of the surgical exploration.

## Surgical Management

Surgical scrotal exploration was performed by a urologist due to a standard local protocol. General anesthesia was used and the testis was exposed after a mid-scrotal incision. When the torsion of the spermatic cord was evident, detorsion was performed, followed by embedding the testis in warm saline soaked swabs. After reperfusion, the testicle was fixed with three standard self-absorbing sutures and prophylactic contralateral scrotal orchidopexy was performed subsequently. If exploration showed a twisted spermatic cord with a necrotic testis and without spontaneous reperfusion after detorsion, the testis was removed. In the case of an ATT, the appendix was removed. No antibiotic prophylaxis was administered.

## Postoperative Management

All patients were discharged the following day with oral analgetic medication for two to three days. Follow-up examination was primarily performed by a pediatrician after 10 to 14 days. If the time between the first onset of pain and hospital admission was more than six hours or TT was shown to be greater than 360°, follow-up was performed at our outpatient department.

## Statistical Analysis

Statistical analyses were performed using SPSS Statistics (IBM, Version 22, Armonk, NY), with a p-value of  $p < 0.05$  being considered as statistically significant. Differences between the groups were calculated by t-test for independent samples for metric parameters, Mann-Whitney U test for ordinal parameters

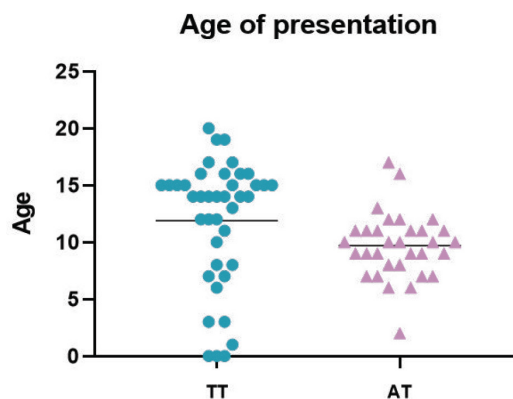
and Pearson chi-square test for nominal parameters. Correlation analyzes were performed using the Cramer-V and Phi coefficient, influence was further evaluated in a logistic regression model. Graphs were created using GraphPad PRISM (GraphPad Software Inc., version 8, San Diego, CA).

## Results

A total of 77 patients were admitted to our department because of acute scrotal pain. Seventy-one scrotal explorations were carried out during the study period. The mean age of our patient cohort was  $10.6 \pm 4.8$  years (range 0-20). Forty-one patients (53.2%) were diagnosed with TT, 32 (41.6%) with ATT, 1 (1.3%) with epididymitis and in 3 (3.9%) patients, no pathology was found intraoperatively. No clinical signs of orchitis were found intraoperatively. The mean duration from onset of symptoms to admission in all cases was 26.3 h, ranging from 1 h to 12 days, in which 49.4% of them were admitted to the hospital less than 6 h after onset. Our cohort included three (3.9%) neonatal cases. No preoperative manual detorsion attempts were performed and no major complications requiring a second surgical intervention or prolonged hospital stay were observed. Table 1 shows the

patient characteristics and the clinical and physical findings in the TT and ATT groups.

There was a significant difference in patient age between the TT and ATT groups, as shown in Figure 1, with the mean age at presentation of  $9.7 \pm 2.9$  years and  $11.9 \pm 5.5$ , respectively ( $p < 0.004$ ).



**Figure 1.** Age at presentation. There was a significant difference in the age of presentation between the group diagnosed with TT and ATT ( $p < 0.004$ )

TT: Testicular torsion, ATT: Appendix testis torsion

Table 1. Patient characteristics			
Variables	TT, n (%)	ATT, n (%)	p-value
Patients	41	32	
Underwent orchiectomy	5	0	0.041
<b>Age (years)</b>			
Mean $\pm$ SD	$11.9 \pm 5.5$	$9.7 \pm 2.9$	0.032
Median (range)	14 (0-20)	10 (2-17)	
<b>Symptom onset (time)</b>			
7 am - 7 pm	18 (43.9)	26 (81.3)	0.001
7 pm - 7 am	23 (56.1)	6 (18.7)	
<b>Time from admission to surgery (hours)</b>			
Mean $\pm$ SD	$1.58 \pm 1.7$	$2.62 \pm 2.7$	0.018
Median (range)	1 (1-8)	2 (1-14)	
<b>Clinical criteria</b>			
Absent cremasteric reflex	38 (92.7)	4 (12.5)	<0.001
Testicular swelling	40 (97.6)	29 (90.6)	0.196
High-riding testis	31 (75.6)	3 (9.4)	<0.001
<b>Clinical scoring</b>			
0/3 criteria	1 (2.4)	2 (6.3)	0.416
1/3 criteria	4 (9.8)	24 (75)	<0.001
2/3 criteria	6 (14.6)	6 (18.8)	0.638
3/3 criteria	30 (73.2)	0 (0)	<0.001
<b>CDUS</b>			
Perfusion	8 (19.5)	32 (100)	<0.001
Absent perfusion	33 (80.5)	0 (0)	

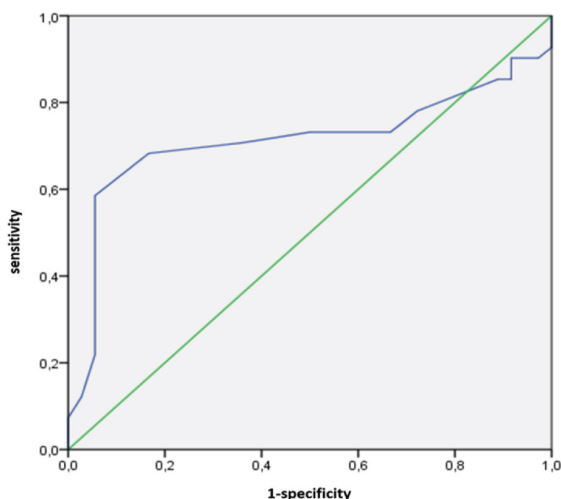
SD: Standard deviation, CDUS: Colour-Doppler ultrasonography, TT: Testicular torsion, ATT: Appendix testis torsion

To evaluate the influence of age as a discriminating factor of TT, a receiver operating characteristic curve analysis was performed and showed an area under the curve of 0.71 (Figure 2).

When defining a cut-off age of 10 years, significance was shown for the presence of TT between the two groups older and younger than 10 years ( $p < 0.001$ ). For this cut-off age, sensitivity is 70.7% and specificity is 63.9% for diagnosis of TT, resulting in a positive predictive value of 69%, a negative predictive value of 65.7% and a likelihood ratio of 1.96, meaning that patients with scrotal pain and an age of more than 10 years are 1.96 times more likely to suffer from TT than from ATT.

The duration from admission to surgery was  $1.56 \pm 0.18$  h in the TT group and  $2.62 \pm 0.53$  h in the ATT group. In five patients with TT (12.2%), orchiectomy had to be performed because the testis already become necrotic, two of them being perinatal patients, of which or cohort had three. In cases of orchiectomy, mean time from symptom onset to admission was 51.8 (range 9-88) hours, which was significantly longer than in those patients, in whom the testis could be preserved, which had with a mean time of 6 (range 1-48) hours ( $p < 0.032$ ). Time between hospital admission and surgical exploration was not significantly different between the two groups, with  $1.8 \pm 0.8$  h in the ATT group and  $2.15 \pm 2.14$  h in the TT group ( $p = 0.716$ ).

Twenty-three (56.1%) patients with TT had an onset of symptoms during the night between 7 p.m. and 7 a.m. A significant correlation between symptom onset and diagnosis of TT and ATT could be shown ( $p < 0.001$ ) resulting in a more frequent onset of symptoms of TT during night-time. Age ( $p < 0.004$ ) and time of onset of symptoms during the night ( $p < 0.006$ ) were significant factors for predicting TT. In a binary logistic regression model, age, as well as onset of symptoms, proved to be significant factors in predicting the presence of TT ( $R^2 = 22.3$ ).



**Figure 2.** Receiver operating characteristic curve analysis showing an area under the curve of 0.71 for a cut-off age of older than 10 years

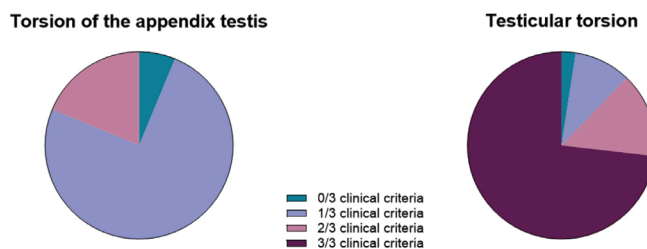
In 36 (87.8%) patients with TT, two out of the three defined clinical criteria were present. In contrast, only 6 (18.8%) of the boys with ATT showed the same number of clinical criteria at presentation ( $p < 0.001$ ). The overall distribution of the presence of clinical criteria is shown in Figure 3.

In patients who had at least two out of three clinical criteria, time from hospital admission to surgery was  $1.82 \pm 0.18$  h. There was a significant correlation between the absence of the cremasteric reflex and the presence of TT, as confirmed by the chi-square test ( $p < 0.0001$ ). The absence of the cremasteric reflex has shown to have a sensitivity of 92.7% and specificity of 80.6%. The absence of this reflex therefore had a positive predictive value of 84.4% for the presence of TT and a negative predictive value of 90.6%. The sensitivities of the presence of scrotal swelling were 97.6% and specificity 8.3%. In cases of high-riding testes, these values were 75.6% and 88.9%, respectively.

All our patients had CDUS before surgical exploration. Thirty-three (80.5%) patients with TT had no perfusion of the involved testis, whereas in the ATT group, perfusion was present in all cases. CDUS findings were significant and strongly correlated with the presence of TT, as shown by Fisher's exact test ( $p < 0.0001$ ). Follow-up data in our outpatient department were documented in nine patients in the TT group and eight in the ATT group. Clinical examination was normal with no signs of residual swelling or tenderness. On CDUS all testes showed a normal perfusion pattern. There were no cases of retorsion, atrophy after testicular fixation, or any other surgical long-term complications.

## Discussion

TT is a pediatric urological emergency, accounting for 10% to 15% cases with acute scrotal pain (17). Moreover, TT is the third most common cause for malpractice lawsuits in adolescent males, emphasizing precaution in this sensitive topic (18). Surgical intervention within eight hours maximum is mandatory to prevent testicular loss or long-term impairment (6,19). The delayed presentation at admission cannot be influenced by



**Figure 3.** The overall distribution of the presence of clinical criteria in both groups

hospital management, so prompt diagnosis upon arrival is essential. In the past, most cases with acute scrotal pain were treated surgically, leading to unnecessarily high-exploration rates including the risks of general anesthesia. TT presented with a peak age of 11.9 years and ATT had a peak age of 9.7 (20,21). There was a significant difference in the age at presentation between both groups, indicating that age younger than 10 may be a useful predictor of ATT (22,23).

The correlation between the daytime onset of symptoms and the presence of TT was significant, showing a more frequent occurrence during night hours, as described by Fujita et al. (23). Late presentation to the hospital is described as the major cause leading to orchiectomy (24,25). This was likewise observed in our cohort, suggestive of low public awareness with respect to acute scrotal pain.

CDUS is commonly discussed as a specific method for differentiating TT from other causes of acute scrotal pain. It is widely used, but in clinical practice, this imaging method is highly dependent on the technique, expertise and routine of the examiner. False-negative results can be seen in TT, as is the case when systolic pressure is measurable, but diastolic pressure is absent due to twisting of the spermatic cord (26). Reactive hyperemia of the tunica vaginalis can accidentally be interpreted as arterial flow into the testis, it is therefore crucial to ensure that the blood flow that is visualized does indeed come from central vessel branches (27). Using CDUS, testicular arterial flow could be visualized in 19% of our patients, although the torsion of the spermatic cord was verified at surgery. It should be emphasized, that performing CDUS was shown to result in an up to 60-minute delay in treatment (28). CDUS should not question the findings of physical examination and therefore certainly not assign or detain patients from surgical intervention. This is in agreement with previous observations (16) and points out that TT cannot be efficiently diagnosed or ruled out using CDUS (14). Waiving of time-consuming imaging should shorten the time to surgery and help salvage testicular tissue since according to our results 50% presented six hours after onset of symptoms.

The clinical criteria triad, consisting of an absence of cremasteric reflex, swelling and high-riding testes, are widely used for symptoms indicative or strongly associated with TT (5). None of the criteria alone can prove the presence of TT, nevertheless, a combination of two or three of these criteria reliably predicted TT in 87% of our cases. The presence of the cremasteric reflex is observed in 61-100% boys between 24 months and 12 years of age (29). Absence of the cremasteric reflex alone therefore is a simple method with high sensitivity for TT (30) with verified sensitivity of 92.7% and specificity of 80.6% in our cohort.

Sheth et al. (28) developed a scoring system based on clinical criteria, assigning presenting patients to a low, intermediate,

and high-risk group. The score allocates high-risk patients to immediate surgical intervention, avoiding possible time delay. Similar to our study, the authors found that no or only one clinical criterion was a powerful predictor to exclude the presence of TT. General agreement that the diagnosis of TT should primarily rely on physical examination, so that the scrotal exploration is not delayed by imaging procedures and treatment costs are kept low (5,7). The limitations were the study retrospective design, furthermore, evaluating clinical criteria depended on interobserver variability. Prospective studies on a larger number of patients are needed to confirm our findings.

## Conclusion

TT is the most common diagnosis of acute scrotal pain after surgical exploration. Latter carries the risk of anesthesia and perioperative adverse events, therefore the ambition is to avoid surgical intervention if justified. Our proposed approach to distinguish between TT and ATT in cases of acute scrotal pain is consistent with using a clinical triad, which can be implemented quickly. Age older than 10 years and onset of symptoms during night hours support the diagnosis of TT. CDUS should not replace clinical evaluation. The traditional approach of physical examination to diagnose TT is safe and effective, hence it should remain the standard approach to assess patients with acute scrotal pain.

## Ethics

**Ethics Committee Approval:** The project was approved by the local medical research ethics committee with the number 1393/2020.

**Informed Consent:** Retrospective study.

**Peer-review:** Externally peer-reviewed.

## Authorship Contributions

Surgical and Medical Practices: R.M., A.K.L., C.R., Concept: R.M., A.K.L., C.R., Design: R.M., A.K.L., C.R., Data Collection or Processing: R.M., A.K.L., C.M., G.L., F.A., C.R., Analysis or Interpretation: R.M., A.K.L., C.M., G.L., F.A., C.R., Literature Search: R.M., A.K.L., C.M., C.R., Writing: R.M., A.K.L.

**Conflict of Interest:** No conflict of interest was declared by the authors.

**Financial Disclosure:** The authors declare that they have no relevant financial.

## References

1. Mansbach JM, Forbes P, Peters C. Testicular torsion and risk factors for orchiectomy. Arch Pediatr Adolesc Med 2005;159:1167-1171.

2. Zhao LC, Lautz TB, Meeks JJ, Maizels M. Pediatric testicular torsion epidemiology using a national database: incidence, risk of orchiectomy and possible measures toward improving the quality of care. *J Urol* 2011;186:2009-2013.
3. Yang C, Song B, Tan J, Liu X, Wei GH. Testicular torsion in children: a 20-year retrospective study in a single institution. *ScientificWorldJournal* 2011;11:362-368.
4. Sharp VJ, Kieran K, Arlen AM. Testicular torsion: diagnosis, evaluation, and management. *Am Fam Physician* 2013;88:835-840.
5. Boettcher M, Bergholz R, Krebs TF, Wenke K, Aronson DC. Clinical predictors of testicular torsion in children. *Urology* 2012;79:670-674.
6. Visser AJ, Heyns CF. Testicular function after torsion of the spermatic cord. *BJU Int* 2003;92:200-203.
7. Srinivasan A, Cinman N, Feber KM, Gitlin J, Palmer LS. History and physical examination findings predictive of testicular torsion: an attempt to promote clinical diagnosis by house staff. *J Pediatr Urol* 2011;7:470-474.
8. Rabinowitz R. The importance of the cremasteric reflex in acute scrotal swelling in children. *J Urol* 1984;132:89-90.
9. Jacob M, Barteczko K. Contribution to the origin and development of the appendices of the testis and epididymis in humans. *Anat Embryol (Berl)* 2005;209:287-302.
10. Mushtaq I, Fung M, Glasson MJ. Retrospective review of paediatric patients with acute scrotum. *ANZ J Surg* 2003;73:55-58.
11. Pomajzl AJ, Leslie SW. StatPearls: Appendix Testes Torsion. Treasure Island (FL); 2020.
12. Cost NG, Bush NC, Barber TD, Huang R, Baker LA. Pediatric testicular torsion: demographics of national orchiopexy versus orchiectomy rates. *J Urol* 2011;185:2459-2463.
13. Kalfa N, Veyrac C, Baud C, Couture A, Averous M, Galifer RB. Ultrasonography of the spermatic cord in children with testicular torsion: impact on the surgical strategy. *J Urol* 2004;172:1692-5; discussion 1695.
14. Frauscher F, Klauser A, Radmayr C. Ultrasonographic assessment of the scrotum. *Lancet* 2001;357:721-722.
15. Canpolat M, Yucel S, Sircan-Kucuksayan A, Kol A, Kazanci HO, Denkceken T. Diagnosis of testicular torsion by measuring attenuation of dual wavelengths in transmission geometry across the testis: an experimental study in a rat model. *Urology* 2012;79:966.e9-12.
16. Kalfa N, Veyrac C, Lopez M, Lopez C, Maurel A, Kaselas C, Sibai S, Arena F, Vaos G, Bréaud J, Merrot T, Kalfa D, Khochman I, Mironescu A, Minaev S, Avérous M, Galifer RB. Multicenter assessment of ultrasound of the spermatic cord in children with acute scrotum. *J Urol* 2007;177:297-301; discussion 301.
17. McAndrew HF, Pemberton R, Kikiros CS, Gollow I. The incidence and investigation of acute scrotal problems in children. *Pediatr Surg Int* 2002;18:435-437.
18. Selbst SM, Friedman MJ, Singh SB. Epidemiology and etiology of malpractice lawsuits involving children in US emergency departments and urgent care centers. *Pediatr Emerg Care* 2005;21:165-169.
19. Kapoor S. Testicular torsion: a race against time. *Int J Clin Pract* 2008;62:821-827.
20. Melekos MD, Asbach HW, Markou SA. Etiology of acute scrotum in 100 boys with regard to age distribution. *J Urol* 1988;139:1023-1025.
21. Appelbaum R, Azari S, Clement M, Browne M. Testicular torsion: The unexpected terrible twos, a unique case report. *Journal of Pediatric Surgery Case Reports* 2019;50:101307.
22. Molokwu CN, Somani BK, Goodman CM. Outcomes of scrotal exploration for acute scrotal pain suspicious of testicular torsion: a consecutive case series of 173 patients. *BJU Int* 2011;107:990-993.
23. Fujita N, Tambo M, Okegawa T, Higashihara E, Nutahara K. Distinguishing testicular torsion from torsion of the appendix testis by clinical features and signs in patients with acute scrotum. *Res Rep Urol* 2017;9:169-174.
24. Tryfonas G, Violaki A, Tsikopoulos G, Avtzoglou P, Zioutis J, Limas C, Gregoriadis G, Badouraki M. Late postoperative results in males treated for testicular torsion during childhood. *J Pediatr Surg* 1994;29:553-556.
25. Rampaul MS, Hosking SW. Testicular torsion: most delay occurs outside hospital. *Ann R Coll Surg Engl* 1998;80:169-172.
26. Lin EP, Bhatt S, Rubens DJ, Dogra VS. Testicular torsion: twists and turns. *Semin Ultrasound CT MR* 2007;28:317-328.
27. Favorito LA, Cavalcante AG, Costa WS. Anatomic aspects of epididymis and tunica vaginalis in patients with testicular torsion. *Int Braz J Urol* 2004;30:420-424.
28. Sheth KR, Keays M, Grimsby GM, Granberg CF, Menon VS, DaJusta DG, Ostrov L, Hill M, Sanchez E, Kuppermann D, Harrison CB, Jacobs MA, Huang R, Burgu B, Hennes H, Schlomer BJ, Baker LA. Diagnosing Testicular Torsion before Urological Consultation and Imaging: Validation of the TWIST Score. *J Urol* 2016;195:1870-1876.
29. Mellick LB, Mowery ML, Al-Dhahir MA. StatPearls: Cremasteric Reflex. Treasure Island (FL); 2020.
30. Nelson CP, Williams JF, Bloom DA. The cremasteric reflex: a useful but imperfect sign in testicular torsion. *J Pediatr Surg* 2003;38:1248-1249.