

Alleviating Effect of Alpha-Pinene on Testicular Torsion and Detorsion Injury in Rats

✉ Selim Demir¹, ✉ İlke Onur Kazaz², ✉ Zeynep Sağnak Yılmaz³, ✉ Nihal Türkmen Alemdar^{4,5}, ✉ Elif Ayazoğlu Demir⁶, ✉ Recep Serhat Tepe², ✉ Ahmet Mentеше⁷

¹Karadeniz Technical University Faculty of Health Sciences, Department of Nutrition and Dietetics, Trabzon, Türkiye

²Karadeniz Technical University Faculty of Medicine, Department of Urology, Trabzon, Türkiye

³Karadeniz Technical University Faculty of Medicine, Department of Pathology, Trabzon, Türkiye

⁴Karadeniz Technical University Institute of Health Sciences, Department of Medical Biochemistry, Trabzon, Türkiye

⁵Recep Tayyip Erdogan University Vocational School of Health Services, Department of Medical Services and Techniques, Rize, Türkiye

⁶Karadeniz Technical University Maçka Vocational School, Department of Chemistry and Chemical Processing Technologies, Trabzon, Türkiye

⁷Karadeniz Technical University Faculty of Medicine, Department of Medical Biochemistry, Trabzon, Türkiye

What's known on the subject? and What does the study add?

Testicular torsion is one of the most important pediatric emergencies. The ischemia/reperfusion injury (IRI) that occurs during detorsion, which is a mandatory treatment, can adversely affect fertility. The search for compounds that can therefore eliminate reperfusion injury has gained momentum. Alpha-pinene (AP) is a monoterpene and is known for its strong antioxidant and anti-inflammatory properties. In this study, it was revealed that oxidative stress, inflammation, and endoplasmic reticulum stress increased and caused testicular damage in the testicular IRI model created in rats. It was determined that AP treatment eliminated this damage. This experimental study provides an important background for subsequent clinical trials on the protective efficacy of AP in cases of testicular torsion.

Abstract

Objective: It was aimed to evaluate whether alpha-pinene (AP) had a beneficial effect in the testicular ischemia/reperfusion injury (IRI) model for the first time.

Materials and Methods: Testicular malondialdehyde, total oxidant status, and total antioxidant status levels were determined using spectrophotometric methods. The superoxide dismutase (SOD), glutathione (GSH), glutathione peroxidase (GPx), myeloperoxidase (MPO), 78-kDa glucose-regulated protein (GRP78), activating transcription factor 6 (ATF6), and C/EBP homologous protein (CHOP) levels were determined using the commercial enzyme-linked immunosorbent assay kits. Hematoxylin-eosin staining method was used in the histopathological evaluation.

Results: In the IRI group, testicular MDA, MPO, GRP78, ATF6, and CHOP levels were significantly increased, while GSH and GPx levels were decreased compared with the control group ($p < 0.01$). AP application restored these levels significantly ($p < 0.05$). Johnsen scores were also significantly lower in the IRI group compared the control group ($p < 0.001$), and AP treatment increased these scores significantly ($p < 0.001$).

Conclusion: These results suggest that AP can protect the testicular tissue against IRI by inhibiting oxidative stress, inflammation, and endoplasmic reticulum stress with its antioxidant properties, thus providing a molecular basis for a novel medical treatment of testicular IRI. Future studies are needed on other mechanisms of the protective effect of AP on the pathogenesis of testicular torsion.

Keywords: Alpha-pinene, endoplasmic reticulum stress, inflammation, oxidative stress, testicular torsion

Correspondence: Selim Demir PhD, Karadeniz Technical University Faculty of Health Sciences, Department of Nutrition and Dietetics, Trabzon, Türkiye

Phone: +90 462 377 78 72 **E-mail:** selim-demir@hotmail.com **ORCID-ID:** orcid.org/0000-0002-1863-6280

Received: 30.09.2022 **Accepted:** 05.02.2023

Cite this article as: Demir S, Kazaz İO, Sağnak Yılmaz Z, Türkmen Alemdar N, Ayazoğlu Demir E, Tepe RS, Mentеше A. Alleviating Effect of Alpha-Pinene on Testicular Torsion and Detorsion Injury in Rats. J Urol Surg, 2023;10(3):253-258.

©Copyright 2023 by the Association of Urological Surgery / Journal of Urological Surgery published by Galenos Publishing House.

Licensed by Creative Commons Attribution-NonCommercial-NoDerivatives (CC BY-NC-ND) 4.0 International License.



Introduction

Testicular torsion (TT) is a urological emergency that causes occlusion of blood vessels and prevents the perfusion of the testicles (1). The annual incidence of TT is reported to be 3.8-8.6 cases per 100,000 men younger than 18 years of age (2). Today, the only mandatory treatment method for TT is detorsion (1,2). However, reperfusion to cause tissue damage more severe than ischemia, this is known as ischemia/reperfusion injury (IRI) and is the main mechanism underlying the pathogenesis of TT (3). During reperfusion of ischemic tissue, excessive amounts of reactive oxygen species (ROS) are formed in the tissue, and these ROS cause endothelial dysfunction, inflammation, lipid peroxidation, and endoplasmic reticulum (ER) stress (3,4). The ER is a cellular organelle involved in protein synthesis, calcium storage, lipid synthesis, detoxification, and energy metabolism (5). Various pathological stimuli, such as increased pressure, temperature, trauma, ROS levels, and nutrient deficiency cause the accumulation of unfolded/misfolded proteins in the ER lumen, and this is known as "ER stress" (6). Cells activate the unfolded protein response (UPR) pathway, which is considered a protective mechanism for eliminate ER stress. In the case of mild ER stress, the activation of the UPR activates the cytoprotective mechanisms, while in the case of severe ER stress, the UPR activates apoptosis (5,6). Recent evidence has revealed that increased ER stress plays a role in the etiopathogenesis of IRI (7). It is therefore suggested that IRI-induced tissue loss can be prevented by identifying compounds with potential ER stress inhibitory activity (5,6).

Terpenoids are among the most abundant components in natural products, and more than 50,000 terpenoid derivatives have been isolated to date (8). Alpha-pinene (AP) is a monoterpene, especially abundant in plants of the *Pinus* genus (9). Today, it has a substantial area of use in the cosmetics, paint and food industries (10). Various pharmacological activities of AP, such as anticoagulant, anti-inflammatory, antimicrobial, antioxidant, antitumor, anti-apoptotic, analgesic, hypoglycemic, neuroprotective, and gastroprotective have been reported (8-10). Although AP protects brain and heart tissues in various experimental IRI models previously (11,12), there is no study examining the protective effect of AP against I/R-induced testicular damage. Protecting male reproductive health against IRI is critical for the continuation of fertility. This study therefore evaluated whether AP had a beneficial effect in a rat testicular IRI model for the first time, which had previously shown antioxidant and anti-inflammatory properties and tissue protective effects in various experimental IRI models.

Materials and Methods

Experimental Design

All experimental procedures were approved by the Animal Experiments Local Ethics Committee of Karadeniz Technical University in accordance with the international guidelines for the use and care of laboratory animals (protocol number: 2022/08, date: 02.03.2022). All surgical procedures were performed under general anesthesia provided by intraperitoneal (ip) administration of 60 mg/kg ketamine (60 mg/kg, Vem Pharmaceuticals, Ankara, Turkiye) and 12 mg/kg xylazine (10 mg/kg, Bayer, Leverkusen, Germany) combination. All applications to the rats were done by the ip route. The scrotal skin area was shaved and cleaned with a betadine antiseptic solution. The left testicle was entered with a scrotal incision, and the left testicle was made visible. The animals were divided into three groups (n=6): Group 1 (sham control), Group 2 (torsion/detorsion, T/D), and Group 3 (T/D+AP, 50 mg/kg). The experimental procedure is briefly summarized in Table 1. In the Group 1, the left testicle was removed and placed back into the scrotum to create surgical stress.

The experimental T/D procedure was performed according to the method by Turner et al. (13). In Groups 2 and 3, the left testicle removed by incision was rotated 720° clockwise and fixed to the scrotum (4,13). After 4 h of ischemia, the suture was removed and testicular reperfusion was achieved for 2 h based on previously described methods (4,14). AP (50 mg/kg) was administered 30 min before detorsion to Group 3. Simultaneously, dimethyl sulfoxide (DMSO) was administered to the Group 1 and Group 2. The dose of AP (Sigma-Aldrich, St. Louis, MO, USA) was determined considering previous studies and was prepared by dissolving in DMSO (12,15). After 2 h of detorsion, orchietomy was performed. The removed testicles were homogeneously divided longitudinally two pieces, and one portion was frozen at -80 °C for biochemical analysis, and the other was stored in Bouin's solution for histological evaluation (Figure 1).

Histological Analysis

Routine histological tissue follow-ups were performed for testicular specimens fixed from Bouin's solution. Testicular specimens were cut in 5 µm sections, stained with H&E, and examined under a light microscope (Olympus BX50, Tokyo, Japan) (4,16). Later, seminiferous tubule architecture and the levels of spermatogenesis were graded with the scoring system defined by Johnsen (17). Scoring and histological evaluation were performed blindly by a pathologist unaware of the groups.

Biochemical Analysis

Testicle tissues were homogenized in cold saline at 9500 rpm using a homogenizer (IKA, T25 Ultra-Turrax, Staufen, Germany). The homogenates were centrifuged at 1800 x g for 15 min at 4°C. The supernatants were collected and the protein contents were determined using a commercial kit (Pierce BCA Protein Assay Kit, Thermo Scientific, Rockford, IL) according to the manufacturer's instructions and used for biochemical analysis. Testicular malondialdehyde (MDA) levels of all groups were determined according to the method described previously (18), while total oxidant status (TOS) and total antioxidant status (TAS) levels were determined using commercial colorimetric kits (Rel Assay Diagnostics, Gaziantep, Türkiye). The oxidative stress index (OSI) was determined using the following formula (19):

$$\text{OSI (arbitrary unit)} = \frac{\text{TOS } (\mu\text{mol hydrogen peroxide equivalent/L})}{\text{TAS } (\mu\text{mol trolox equivalent/L})} \times 100$$

Tissue superoxide dismutase (SOD), glutathione peroxidase (GPx), glutathione (GSH), myeloperoxidase (MPO), 78-kDa glucose-regulated protein (GRP78), activating transcription factor

6 (ATF6) and C/EBP homologous protein (CHOP) levels were determined using ready-to-use enzyme-linked immunosorbent assay (ELISA) kits (Finetest, Wuhan, China).

Statistical Analysis

All data are expressed as mean ± standard deviation. Statistical differences between the groups were assessed by ANOVA followed by Tukey's Post-hoc test. P was defined as statistically significant at <0.05.

Results

The levels of biochemical parameters and histological scores are presented in Table 2. The data showed that the MDA, TOS, OSI, and MPO levels in Group 2 were significantly more than Group 1 (p=0.0001, p=0.001, p=0.017 and p=0.0001, respectively). In contrast, the treatment of rats with AP, which was administered before reperfusion significantly lowered MDA, TOS, OSI and MPO levels compared to Group 2 (p=0.0001, p=0.003, p=0.025 and p=0.0001, respectively).

The results showed that the tissue levels of TAS, SOD, GPx, and GSH were significantly decreased in the Group 2 compared to Group 1 (p=0.0001, p=0.0001, p=0.003 and p=0.0001, respectively). In contrast, the administration of AP before reperfusion caused a significant increase in the tissue levels of TAS, SOD, GPx and GSH compared to Group 2 (p=0.0001, p=0.0001, p=0.006 and p=0.001, respectively).

Additionally, the GRP78, ATF6, and CHOP levels of the Group 2 were significantly increased compared with Group 1 (p=0.0001, p=0.001 and p=0.0001, respectively). Contrarily, treatment of rats with AP significantly decreased the tissue levels of GRP78, ATF6 and CHOP compared to Group 2 (p=0.0001, p=0.002 and p=0.0001, respectively). Furthermore, no significant difference was found between the Groups 1 and 3 in terms of biochemical parameters (p>0.05).

Johnsen scores were significantly lower in the Group 2 compared to Group 1 (p=0.0001), and AP treatment increased these scores significantly (p=0.0001).

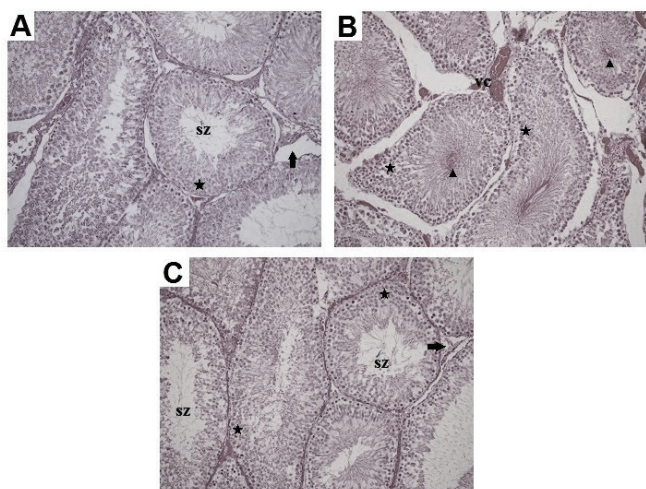


Figure 1. Histopathological images of testicular tissues of groups (×200, H&E staining). **Control Group (A)** SZ: spermatozoon, black star: seminiferous tubule germinal epithelium, black arrow: intertubular area. **T/D Group (B)** VC: vasocongestion in the intertubular area, arrowhead: germinal epithelial cells, black star: seminiferous tubule germinal epithelium. **T/D+AP Group (C)** SZ: spermatozoon, black star: seminiferous tubule germinal epithelium, black arrow: intertubular area

	Groups		
	Control	T/D	AP + T/D
Torsion 0 min	-	+	+
210 min after torsion	DMSO	DMSO	50 mg/kg
Detorsion (240 min after torsion)	-	+	+
Orchiectomy (360 min after torsion)	+	+	+

T/D: torsion/detorsion; AP: (+)-alpha-pinene

Table 2. The levels of oxidative stress, inflammation and ER stress markers and Johnsen scores of groups

	Control	T/D	AP + T/D
MDA (nmol/mg protein)	4.53±2.91	14.9±3.08 ^a	5.55±0.81 ^b
TOS (µM H ₂ O ₂ equivalent/L)	22.7±2.90	54.2±18.1 ^a	26.6±8.82 ^b
TAS (mM trolox equivalent/L)	1.18±0.12	0.62±0.23 ^a	1.03±0.08 ^b
OSI (arbitrary unit)	1.97±0.21	11.1±8.66 ^a	2.53±0.81 ^b
SOD (ng/mg protein)	0.24±0.05	0.09±0.03 ^a	0.21±0.03 ^b
GPx (pg/mg protein)	16.4±4.34	8.88±1.98 ^a	15.9±3.09 ^b
GSH (µg/mg protein)	4.82±1.42	0.85±0.26 ^a	4.52±1.80 ^b
MPO (ng/mg protein)	0.32±0.08	1.26±0.45 ^a	0.33±0.09 ^b
GRP78 (pg/mg protein)	51.7±7.81	160.3±38.2 ^a	42.3±6.87 ^b
ATF6 (pg/mg protein)	30.4±6.56	55.6±12.8 ^a	33.9±6.54 ^b
CHOP (ng/mg protein)	0.25±0.07	0.77±0.30 ^a	0.21±0.04 ^b
Johnsen Score	9.5±0.55	4.33±1.21 ^a	8.0±0.63 ^{a,b}

T/D: Torsion/detorsion, AP: (+)-alpha-pinene, MDA: Malondialdehyde, TOS: Total oxidant status, TAS: Total antioxidant status, OSI: Oxidative stress index, SOD: Superoxide dismutase, GPx: Glutathione peroxidase, GSH: Glutathione, MPO: Myeloperoxidase, GRP78: 78-kDa glucose-regulated protein, ATF-6: Activating transcription factor-6, CHOP: C/EBP homologous protein, P-values according to one-way ANOVA test, post-hoc Tukey test. Data were expressed as mean±SD. ^ap<0.05 compared with control group, ^bp<0.05 compared with T/D group

Discussion

TT is one of the most serious pediatric emergencies, and IRI is central to its pathogenesis (1,2). The pathogenesis of IRI is complex and is related to various molecular mechanisms, such as oxidative/nitrosative stress, inflammation, ER stress, and mitochondrial dysfunction (3). In particular, MDA, a byproduct of the oxidation of fatty acids, acts as a potent chemoattractant and initiates the proinflammatory phase in tissues (20). It is therefore stated that there is a correlation between MDA levels and tissue oxidative stress level (4). TOS, TAS, and OSI are popular cumulative oxidative stress indicators that reveal the level of oxidative stress in biological samples (19,21). Increased MDA, TOS, and OSI levels and lower TAS levels in Group 2 indicated that the testicular IRI was mediated by oxidative stress, while AP treatment significantly reduced this damage in this study. Consistent with our results, AP has been previously demonstrated to prevent IRI-induced brain and heart injury by decreasing oxidative stress levels (11,12).

SOD is the primary step of the antioxidant defense mechanism in the organism and catalyzes the conversion of superoxide to hydrogen peroxide (22). GSH is a molecule synthesized from glutamic acid, cysteine and glycine, with a high antioxidant potential due to its sulfhydryl groups (23). GPx is an enzyme that reduces hydrogen peroxide to water with the antioxidant property of GSH (12). Measurements of GSH, SOD and GPx are therefore frequently preferred biochemical parameters to determine the level of antioxidant defense system in a biological sample (21). The results showed that decreased GSH, SOD and GPx levels in Group 2 could not protect the testicular tissue against ROS attacks (24), while AP treatment strengthened

the antioxidant mechanism. This may be because AP protects antioxidant defense systems from attack by ROS. Similar to our results, AP has previously been demonstrated to prevent I/R, hydrogen peroxide, and scopolamine-induced intestine and brain injuries by increasing antioxidant enzyme levels (15,22,25).

Inflammation is an important biological reaction of the organism in response to external stimuli (26). Neutrophil infiltration is another characteristic of IRI-induced inflammatory tissue damage. Migration and activation of neutrophils into the ischemic tissue increase the amount of ROS, MPO, and pro-inflammatory cytokines and exacerbate tissue damage (20). While the increased MPO levels in Group 2 showed that testicular IRI was mediated by inflammation, it was determined that AP abolished this damage with its previously revealed anti-inflammatory properties. Similar to our results, terpenoids have previously been demonstrated to prevent I/R and cyclophosphamide-induced brain and testicular injuries via reducing the inflammation (20,27).

Recent studies highlight that ER stress comes to the forefront as an important molecular mechanism in IRI. ER stress from ischemic injury initiates the UPR, which is considered a protection mechanism (7). Three sensor proteins detect ER stress and initiate the UPR pathway: inositol-requiring enzyme-1 alpha (IRE-1α), protein kinase-like ER kinase (PERK), and ATF6 (28). Under physiological conditions, these three proteins are inactive and bound to GRP78, a large molecular ER chaperone. Under conditions of increased ER stress, GRP78 cleaves from PERK, IRE1, and ATF6, and this cleavage activates these sensor proteins (7). After ATF6 dissociates with GRP78, it is transported to the golgi in response to ER stress. Released ATF6 passes

into the golgi, where it is cleaved by proteases and activated. Activated ATF6 migrates from the golgi to the nucleus where it induces the expression of proteins in optimizing protein folding, maturation, and elimination of missense proteins (4). In the case of excessive ER stress, ATF6 induces CHOP expression, resulting in apoptosis and elimination of the cell whose ER stress cannot be reduced. Under increased ER stress conditions, increased CHOP suppresses Bcl-2 and GSH levels, increases Bax and ROS levels and causes the activation of apoptosis (4,28). Studies recently have focused on strategies that target the inhibition of ER stress in the I/R process. Among them, the treatment method with molecules with antioxidant and anti-inflammatory properties attracted great attention (29). However, there was no study examining the effect of AP on IRI-induced ER stress. The results showed that the levels of ER stress markers increased in the IRI group, whereas AP protected the testicular tissue against IRI by suppressing ER stress. Similar to our results, terpenoids have previously been demonstrated to prevent liver and lung IRI via reducing the ER stress (28,29).

Histological evaluation is a critical method in evaluating tissue damage caused by IRI and revealing the degree of the therapeutic effect of the investigated molecule (4,16). Histological analysis confirmed that functional testicular structures were damaged in the IRI group, while AP successfully attenuated this damage. In parallel with our results, it is previously shown histologically that various terpenoids, including eugenol and nerolidol, protect the testicular tissue against the damage caused by cisplatin and cyclophosphamide by modulating oxidative stress, inflammation, and apoptosis (20,30).

Study Limitations

There are also some limitations to our study. First, only one dose of AP was evaluated on the basis of literature data within the scope of this study. Second, the efficacy of AP at different times or in chronic T/D conditions was not evaluated in this study. The testicular protective effect of AP at different periods and doses should be evaluated in the next comprehensive studies. Third, the effects of AP on fertility levels were not evaluated in the study. We believe that demonstrating the protective efficacy of AP against testicular IRI in long-term studies with physiological fertility behavior experiments will shed light on the clinical stages.

Conclusion

The results showed that AP reduced the testicular IRI for the first time. This protective effect of AP is thought to be due to its antioxidant, anti-inflammatory and ER stress inhibitor properties. Based on these findings, AP may be useful as a potentially effective adjunct to therapy for ischemic testicular injury before reperfusion.

Ethics

Ethics Committee Approval: This study was approved by the Animal Care Ethical Committee of Karadeniz Technical University (protocol number: 2022/08, date: 02.03.2022) and performed according to the animal research reporting of *in vivo* experiments (ARRIVE) guidelines.

Informed Consent: All institutional and national guidelines for the care and use of laboratory animals were followed. The rights of the animals were respected.

Peer-review: Externally and internally peer-reviewed.

Authorship Contributions

Surgical and Medical Practices: İ.O.K., Z.S.Y., S.D., R.S.T., Concept: S.D., İ.O.K., Design: S.D., İ.O.K., Z.S.Y., A.M., Data Collection or Processing: S.D., Z.S.Y., E.A.D., N.T.A., Analysis or Interpretation: S.D., İ.O.K., Z.S.Y., A.M., Literature Search: S.D., İ.O.K., E.A.D., N.T.A., Writing: S.D.

Conflict of Interest: No conflict of interest was declared by the authors.

Financial Disclosure: The authors declare that they have no relevant financial.

References

1. Laher A, Ragavan S, Mehta P, Adam A. Testicular Torsion in the Emergency Room: A Review of Detection and Management Strategies. *Open Access Emerg Med* 2020;12:237-246.
2. Thaker H, Nelson CP. Adjuvant pharmacological and surgical therapy for testicular torsion: Current state of the art. *J Pediatr Urol* 2020;16:807-814.
3. Arena S, Iacona R, Antonuccio P, Russo T, Salvo V, Gitto E, Impellizzeri P, Romeo C. Medical perspective in testicular ischemia-reperfusion injury. *Exp Ther Med* 2017;13:2115-2122.
4. Kazaz IO, Demir S, Kerimoglu G, Colak F, Turkmen Alemdar N, Yilmaz Dogan S, Bostan S, Mentese A. Chlorogenic acid ameliorates torsion/detorsion-induced testicular injury via decreasing endoplasmic reticulum stress. *J Pediatr Urol* 2022;18:289.e1-289.e7.
5. Gao X, Xu Y. Therapeutic Effects of Natural Compounds and Small Molecule Inhibitors Targeting Endoplasmic Reticulum Stress in Alzheimer's Disease. *Front Cell Dev Biol* 2021;9:745011.
6. Ma RH, Ni ZJ, Thakur K, Zhang F, Zhang YY, Zhang JG, Wei ZJ. Natural compounds play therapeutic roles in various human pathologies via regulating endoplasmic reticulum pathway. *Medicine in Drug Discovery* 2020;8: 100065.
7. Han Y, Yuan M, Guo YS, Shen XY, Gao ZK, Bi X. Mechanism of Endoplasmic Reticulum Stress in Cerebral Ischemia. *Front Cell Neurosci* 2021;15:704334.
8. Yang W, Chen X, Li Y, Guo S, Wang Z, Yu X. Advances in pharmacological activities of terpenoids. *Nat Prod Commun* 2020;15:1-13.
9. Park BB, An JY, Park SU. Recent studies on pinene and its biological and pharmacological activities. *EXCLI J* 2021;20:812-818.
10. Allenspach M, Steuer C. α -Pinene: A never-ending story. *Phytochemistry* 2021;190:112857.
11. Choi IY, Lim JH, Hwang S, Lee JC, Cho GS, Kim WK. Anti-ischemic and anti-inflammatory activity of (S)-cis-verbenol. *Free Radic Res* 2010;44:541-551.

12. Zhang B, Wang H, Yang Z, Cao M, Wang K, Wang G, Zhao Y. Protective effect of alpha-pinene against isoproterenol-induced myocardial infarction through NF- κ B signaling pathway. *Hum Exp Toxicol* 2020;39:1596-1606.
13. Turner TT, Tung KS, Tomomasa H, Wilson LW. Acute testicular ischemia results in germ cell-specific apoptosis in the rat. *Biol Reprod* 1997;57:1267-1274.
14. Mentese A, Demir S, Kazaz IO, Yulug E, Alemdar NT, Demir EA, Kartal MB, Durmus TB, Aliyazicioglu Y. Vanillic acid attenuates testicular ischemia/reperfusion injury in rats. *Beni-Suef Univ J Basic Appl Sci* 2022;11:155.
15. Khoshnazar M, Bigdeli MR, Parvardeh S, Pouriran R. Attenuating effect of α -pinene on neurobehavioural deficit, oxidative damage and inflammatory response following focal ischaemic stroke in rat. *J Pharm Pharmacol* 2019;71:1725-1733.
16. Demir S, Kazaz IO, Kerimoglu G, Ayazoglu Demir E, Colak F, Yilmaz S, Mentese A. Astaxanthin Protects Testicular Tissue against Torsion/Detorsion-Induced Injury via Suppressing Endoplasmic Reticulum Stress in Rats. *J Invest Surg* 2022;35:1044-1049.
17. Johnsen SG. Testicular biopsy score count--a method for registration of spermatogenesis in human testes: normal values and results in 335 hypogonadal males. *Hormones* 1970;1:2-25.
18. Mihara M, Uchiyama M. Determination of malonaldehyde precursor in tissues by thiobarbituric acid test. *Anal Biochem* 1978;86:271-278.
19. Ayazoglu Demir E, Mentese A, Kucuk H, Turkmen Alemdar N, Demir S. p-Coumaric acid alleviates cisplatin-induced ovarian toxicity in rats. *J Obstet Gynaecol Res* 2022;48:411-419.
20. Iqbal A, Syed MA, Najmi AK, Ali J, Haque SE. Ameliorative effect of nerolidol on cyclophosphamide-induced gonadal toxicity in Swiss Albino mice: Biochemical-, histological- and immunohistochemical-based evidences. *Andrologia* 2020;52:e13535.
21. Marrocco I, Altieri F, Peluso I. Measurement and Clinical Significance of Biomarkers of Oxidative Stress in Humans. *Oxid Med Cell Longev* 2017;2017:6501046.
22. Lee GY, Lee C, Park GH, Jang JH. Amelioration of Scopolamine-Induced Learning and Memory Impairment by α -Pinene in C57BL/6 Mice. *Evid Based Complement Alternat Med* 2017;2017:4926815.
23. Ma JQ, Liu CM, Qin ZH, Jiang JH, Sun YZ. Ganoderma applanatum terpenes protect mouse liver against benzo(α)pyren-induced oxidative stress and inflammation. *Environ Toxicol Pharmacol* 2011;31:460-468.
24. Manjunatha S, Shaik AH, E MP, Al Omar SY, Mohammad A, Kodihela LD. Combined cardio-protective ability of syringic acid and resveratrol against isoproterenol induced cardio-toxicity in rats via attenuating NF- κ B and TNF- α pathways. *Sci Rep* 2020;10:3426.
25. Porres-Martínez M, González-Burgos E, Carretero ME, Gómez-Serranillos MP. In vitro neuroprotective potential of the monoterpenes α -pinene and 1,8-cineole against H₂O₂-induced oxidative stress in PC12 cells. *Z Naturforsch C J Biosci* 2016;71:191-199.
26. Afolabi O, Alabi B, Omobowale T, Oluranti O, Iwalewa O. Cysteamine mitigates torsion/detorsion-induced reperfusion injury via inhibition of apoptosis, oxidative stress and inflammatory responses in experimental rat model. *Andrologia* 2022;54:e14243.
27. Mu L, Kou J, Zhu D, Yu B. Comparison of neuroprotective effects of flavonoids, terpenoids, and their combinations from Ginkgo biloba on ischemia-reperfusion-injured mice. *Pharm Biol* 2007;45:728-733.
28. Yang Y, Li C, Liu N, Wang M, Zhou X, Kim IH, Wu Z. Ursolic acid alleviates heat stress-induced lung injury by regulating endoplasmic reticulum stress signaling in mice. *J Nutr Biochem* 2021;89:108557.
29. Bouhlel A, Ben Mosbah I, Hadj Abdallah N, Ribault C, Viel R, Mannaï S, Corlu A, Ben Abdennebi H. Thymoquinone prevents endoplasmic reticulum stress and mitochondria-induced apoptosis in a rat model of partial hepatic warm ischemia reperfusion. *Biomed Pharmacother* 2017;94:964-973.
30. Ekinci Akdemir FN, Yildirim S, Kandemir FM, Aksu EH, Guler MC, Kiziltunc Ozmen H, Kucukler S, Eser G. The antiapoptotic and antioxidant effects of eugenol against cisplatin-induced testicular damage in the experimental model. *Andrologia* 2019;51:e13353.